



COVID-19 Pneumonia, Diabetes and Alteration of the Biochemical Values of Blood: A Case Report and Review of the Literature

**Petronela Vicoveanu¹, Roxana Covali^{2*}, Laura Riscanu³, Demetra Socolov⁴,
Ioana Pavaleanu⁵, Alexandru Carauleanu⁴ and Razvan Socolov⁵**

¹*Department of Obstetrics and Gynecology, "Sf. Ioan Cel Nou" Emergency Hospital, Suceava, Romania.*

²*Department of Radiology, "Elena Doamna" Obstetrics and Gynecology University Hospital, Iasi, Romania.*

³*Institute of Legal Medicine, Iasi, Romania.*

⁴*Department of Obstetrics and Gynecology, "Cuza Voda" Obstetrics and Gynecology University Hospital, Iasi, Romania.*

⁵*Department of Obstetrics and Gynecology, "Elena Doamna" Obstetrics and Gynecology University Hospital, Iasi, Romania.*

Authors' contributions

This work was carried out in collaboration among all authors. Author PV designed the study and performed data curation. Author RC performed data curation and wrote the first draft of the manuscript. Author LR managed the literature search and wrote the first draft of the manuscript. Author DS performed supervision and wrote the final manuscript. Author IP managed the literature searches and wrote the first draft of the manuscript. Author AC performed data curation and wrote the first draft of the manuscript. Author RS managed the analysis of the study and wrote the final manuscript. All authors read and approved the final manuscript.

Article Information

DOI: 10.9734/JAMMR/2021/v33i630865

Editor(s):

(1) Dr. Rameshwari Thakur, Muzaffarnagar Medical College, India.

(2) Dr. Emmanouil (Manolis) Magiorkinis, General Hospital for Chest Diseases "Sotiria", Greece.

(3) Dr. Mohamed Essa, Sultan Qaboos University, Oman.

Reviewers:

(1) Navin Kumar Devaraj, Universiti Putra Malaysia, Malaysia.

(2) Nikol Panou, Greece.

(3) R. Arun Kumar, Bharathidasan University, India.

Complete Peer review History: <http://www.sdiarticle4.com/review-history/66618>

Case Study

Received 10 February 2021

Accepted 16 March 2021

Published 24 March 2021

ABSTRACT

Aims: The variability in evolution of the novel coronavirus has perplexed the medical community. We herein report the case of a patient with specific characteristics, somewhat outside the reported average values.

Presentation of Case: A 60-year-old type I diabetic patient was admitted as an outpatient to a university hospital for the following symptoms: fever up to 38.1°C, malaise, and shortness of breath. Upon admittance, the chest X-ray revealed a homogenous triangular opacity, of medium intensity, located in the lower lobe of the left lung, suggesting pneumonia. Altered biochemistry values in our hospital included ALT = 86U/L, AST = 118 U/L, serum urea = 43.4 mg/dL, serum creatinine = 1.43 mg/dL, fasting blood glucose = 167.9 mg/dL (she had type 1 diabetes and received insulin only in the evening), triglycerides = 214.9 mg/dL, serum magnesium = 1.48 mg/dL, serum iron = 14.1 mg/dL. Fever, malaise, and shortness of breath, together with the X-ray image of the chest suggested COVID-19. RT-PCR confirmed the diagnosis 12 hours later. Three days after admission, she felt dyspneic, and oxygen therapy was administered for 7 days, together with Lopinavir/Ritonavir, Dexamethasone, Heparin and Vitamin C. After 18 days in the hospital, she felt good, and was released from the hospital.

Conclusion: Despite the numerous aggravating factors for COVID-19 (age [60 years old], type 1 diabetes, increased values of ALT, AST, serum urea, serum creatinine, fasting blood glucose, low serum magnesium, one whole lobe pneumonia, and only one favorable factor—low serum iron), the patient survived and recovered.

Keywords: COVID-19; pneumonia; type 1 diabetes; magnesium; iron.

1. INTRODUCTION

A novel coronavirus emerged in China in December 2019 and spread quickly throughout the world, generating a huge burden for medical systems worldwide. The wide range of manifestations and the capacity to infect patients of almost all ages, no matter the previous state of health, perplexed the medical community.

We herein report the case of a patient with specific characteristics, somewhat outside the reported average values. The patient was diabetic, and diabetes was described so far as a major comorbidity factor to determine negative evolution for COVID-19 patients. So was the advanced age, and the liver involvement. Still, against all odds, the patient recovered.

2. CASE PRESENTATION

A 60-year-old patient was admitted on 7/9/2020 at 9.a.m. as an outpatient to a university hospital for the following symptoms: fever up to 38.1°C, malaise, and shortness of breath. The fever is what triggered her coming to the hospital. This was the third day of fever, and common NSAID pills would not diminish it. She had just returned from a summer holiday on the beach. Anamnesis revealed that she was a long-time known type I diabetic patient. She denied smoking or alcohol drinking habits.

Upon admittance, pharynx and nose samples were harvested for the Real-Time PCR (RT-PCR)

test for the Sars-Cov-2 virus. Among other tests, a chest X-ray was performed and blood samples were obtained to determine the biochemical composition of the blood. ALT and AST were determined by International Federation of Clinical Chemistry standardized kinetic method with pyridoxal-5-phosphate. Serum urea, creatinine, triglycerides, magnesium and iron were determined by spectrophotometry. C-reactive protein was determined by latex agglutination. The major risk factors for COVID-19 for this patient were: type I diabetes, age (60 years old), holiday on the beach, where she most probably did not wear mask.

Chest X-ray showed left lower lobe pneumonia (Fig. 1).

Altered biochemistry values in our hospital were as follows: ALT = 86 U/L (normal: 0-31 U/L), AST = 118 U/L (0-31 U/L), serum urea = 43.4 mg/dL (0-45 mg/dL), serum creatinine = 1.43 mg/dL (0-1.15 mg/dL), fasting blood glucose = 167.9 mg/dL (65-115 mg/dL) (she was a type 1 diabetic patient, receiving insulin administration only in the evening), triglycerides = 214.9 mg/dL (<150 mg/dL), C-reactive protein value >6 mg/L (0-6 mg/L), serum magnesium = 1.48 mg/dL (1.6-2.6 mg/dL), and serum iron = 14.1 mg/dL (37-145 mg/dL). All the blood analysis were performed on the same day, 7/9/2020, at 9.36 a.m. Fever, malaise, and shortness of breath, together with the X-ray image of the chest and the fact that she had just returned from a holiday, where she most

probably did not wear a face mask, suggested COVID-19. RT-PCR confirmed the diagnosis 12 hours later, when she was immediately referred to the local infectious disease hospital. Three days after admission, she felt dyspneic and oxygen therapy was administered for 7 days, together with 4 types of medicines (Lopinavir/Ritonavir, 200 mg/day; Dexamethasone, 6 mg/day; Heparin, 100UI/kg/day; Vitamin C, 24 g/day).

3. RESULTS AND DISCUSSION

After 18 days in the hospital, her chest X-ray was normal, she felt good, and she was released from the hospital. RT-PCR was negative 7 days after admission into the hospital. Her contacts, including her family, were also screened, at 5 days and 12 days later, and none tested positive at RT-PCR screening.

Mo et al. [1] showed that, compared with general COVID-19 patients, refractory patients had an older age, male sex, more underlying comorbidities, lower incidence of fever, high levels of aspartate aminotransferase and C-reactive protein, and a higher incidence of bilateral pneumonia and pleural effusion. Our patient was 60 years old (not very old), a female, and had one known comorbidity (type I diabetes). She did complain of fever, up to 38.1°C in the evening. Nonetheless, she still was in a fair state of health. She came to the hospital on her own, and she was able to walk rather quickly to and from the harvesting/laboratory rooms. Her pneumonia was unilateral, and no pleural effusion was visible upon admittance. Her AST value (118 U/L), C-reactive protein value (>6 mg/L), and blood glucose (167.9 mg/dL) were increased; albeit the patient reported high compliance with her medication.

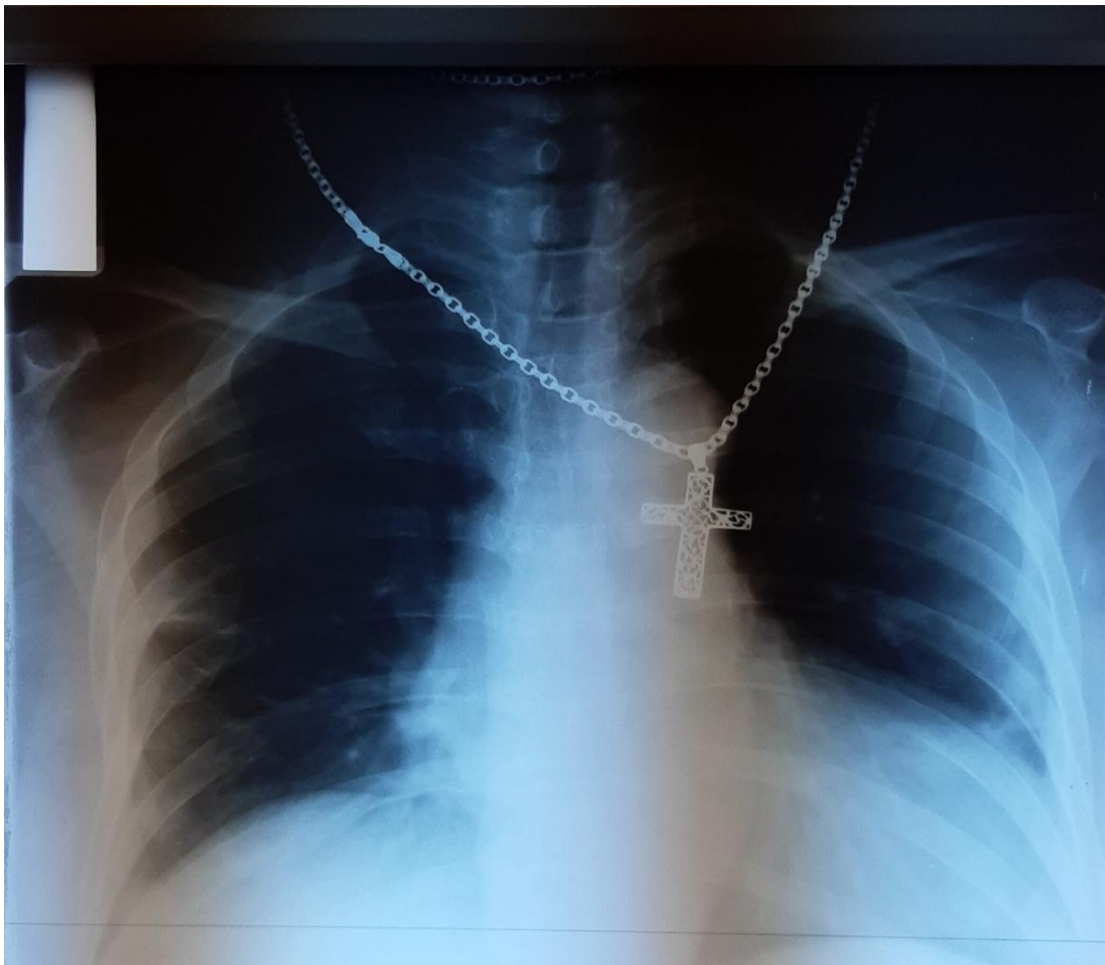


Fig. 1. Pneumonia of the left lower lobe. Chest X-ray

According to Lei et al. [2], AST abnormality was associated with the highest mortality risk compared with other indicators of liver injury during hospitalization. This didn't appear to be true in our case, as the patient recovered despite her high ST value (118U/L), and rather poor health.

Marda et al. [3] reported the mean age for COVID-19 patients as 41 years, mostly males (53%), and with increased values of alanine aminotransferase, aspartate aminotransferase, C-reactive protein, urea in serum, and a lower serum albumin level. In our case we report additionally increased serum urea (43.4 mg/dL) and increased serum creatinine (1.43 mg/dL). To the best of our knowledge, we are the first to report increased serum creatinine. Because Zhang et al. [4] found no significant correlation between increased serum creatinine values and the severe COVID-19 cases, there may be a correlation between diabetes and the increased creatinine value in our patient. The serum albumin level was not determined upon the patient's admittance to our hospital.

Kato et al. [5] reported ground-glass opacity in 97.7% of the patients with pneumonia. Our patient's X-ray did not show ground glass opacities, only condensation of the lower left lobe.

Iotti et al. [6] correlated the magnesium deficiency to a drop in T cells, increased plasma concentration of inflammatory cytokines, which would later trigger the critical manifestations of the disease. This was true in our case, too, because the serum magnesium level (1.48 mg/dL) of the patient was lower than normal, and although she was well enough initially, she required oxygen administration 3 days later.

Van Laecke et al. [7], studying the role of magnesium as a co-factor in natural killer and T cell reactivity, demonstrated that low serum magnesium was associated with an increased risk of infection, every 0.1 mg/dL reduction in serum magnesium at baseline below 2 mg/dL increased the infection hazard ratio by 15%. Our patient had a serum magnesium level under 2 mg/dL (1.48 mg/dL), and she already had COVID pneumonia.

Shi et al. [8] noted that subclinical magnesium deficiency, defined as serum magnesium under 0.85 mmol/L (2.06 mg/dL), was common in Qatar and associated with diabetes, prediabetes, and

hypertension in Qatari adults. So the hypomagnesemia of our patient may be a consequence of her type 1 diabetes, or just the result of inappropriate food magnesium intake. Her blood pressure was normal upon admittance. Edeas et al. [9] showed that the cytokine storm in the hyperinflammatory state of the severely ill COVID-19 patients included hyperferritinemia, which identified patients with increased mortality risk; therefore, the possible role of altered iron homeostasis in COVID-19 pathogenesis should be studied. Edeas et al. [9] also associated hyperferritinemia with a state of iron toxicity, resulting from increased ferritin leakage from damaged tissues, releasing free iron in the process. Our patient had a decreased value of serum iron; therefore, no iron toxicity and no hyperinflammatory state had been triggered and she demonstrated less severe disease.

4. CONCLUSION

Despite numerous aggravating factors for COVID-19, including being 60 years of age, having increased levels of ALT, AST, serum urea, serum creatinine, fasting blood glucose, low serum magnesium, one whole lobe pneumonia, and only one favorable factor, low serum iron, the patient survived and recovered.

CONSENT

All authors declare that 'written informed consent was obtained from the patient for publication of this case report and accompanying image.

ETHICAL APPROVAL

This study received the Elena Doamna Obstetrics and Gynecology University Hospital Research Ethics Committee Approval number 3 from June 10th, 2020.

COMPETING INTERESTS

Authors have declared that no competing interests exist.

REFERENCES

1. Mo P, Xing Y, Xiao Y, Deng L, Zhao Q, Wang H et al. Clinical characteristics of refractory COVID-19 pneumonia in Wuhan, China. *Clin Infect Dis*. 2020;270. DOI: 10.1093/cid/ciaa270. Online ahead of print.

2. Lei F, Liu YM, Zhou F, Qin JJ, Zhang P, Zhu L et al. Longitudinal association between markers of liver injury and mortality in COVID-19 in China. *Hepatology*; 2020. DOI: 10.1002/hep.31301 [Epub ahead of print].
3. Mardani R, Vasmehjani AA, Zali F, Gholami A, Nasab SDM, Kaghazian H, et al. Laboratory parameters in detection of COVID-19 patients with positive RT-PCR; a diagnostic accuracy study. *Arch Acad Emerg Med*. 2020;8(1):e43.
4. Zhang Y, Zheng L, Liu L, Zhao M, Xiao J, Zhao Q. Liver impairment in COVID-19 patients: A retrospective analysis of 115 cases from a single centre in Wuhan city, China. *Liver Int*; 2020. DOI: 10.1111/liv.14455. Online ahead of print.
5. Kato H, Shimizu H, Shibue Y, Hosoda T, Iwabuchi K, Nagamine K et al. Clinical course of 2019 novel coronavirus disease (COVID-19) in individuals present during the outbreak on the Diamond Princess cruise ship. *J Infect Chemoter*. 2020;26(8): 865-869. DOI: 10.1016/j.jiac.2020.05.005.
6. Iotti S, Wolf F, Mazur A, Maier JA. The COVID-19 pandemic: is there a role for magnesium? Hypotheses and perspectives. *Magnes Res*; 2020. DOI:10.1684/mrh.2024.0466. Online ahead of print.
7. Van Laecke S, Vermeiren P, Nagler EV, Caluwe R, De Wilde M, Van der Vennet M et al. Magnesium and infection risk after kidney transplantation: An observational cohort study. *J Infect*. 2016; 73(1):8-17. DOI: 10.1016/j.jinf.2016.04.007. Epub: 2016 Apr 12.
8. Shi Z, Abou Samra AB. Association of low serum magnesium with diabetes and hypertension: findings from Qatar Biobank study. *Diabetes Res Clin Pract* 2019;158: 107903. DOI: 10.1016/j.diabres.2019.107903. Epub: 2019 Oct 31.
9. Edeas M, Saleh J, Peyssonnaud C. Iron: Innocent bystander or vicious culprit in COVID-19 pathogenesis? *Int J Infect Dis*. 2020;97:303-305. DOI: 10.1016/j.ijid.2020.05.110. Epub: 2020 Jun 2.

© 2021 Vicoveanu et al.; This is an Open Access article distributed under the terms of the Creative Commons Attribution License (<http://creativecommons.org/licenses/by/4.0>), which permits unrestricted use, distribution, and reproduction in any medium, provided the original work is properly cited.

Peer-review history:

*The peer review history for this paper can be accessed here:
<http://www.sdiarticle4.com/review-history/66618>*