



## **Foreign Body in the Anterior Chamber Presenting as Inflammatory Mass on the Iris**

**Rajgopal Arvinth<sup>a,b</sup>, Mimiwati Zahari<sup>a</sup> and Sagili Chandrasekhara Reddy<sup>c\*</sup>**

<sup>a</sup> *Department of Ophthalmology, Faculty of Medicine, University of Malaya, Kuala Lumpur, Malaysia.*

<sup>b</sup> *Department of Ophthalmology, Hospital Ampang, Selangor, Malaysia.*

<sup>c</sup> *Department of Ophthalmology, Faculty of Medicine and Defence Health, National Defence University of Malaysia, Kuala Lumpur, Malaysia.*

### **Authors' contributions**

*This work was carried out in collaboration among all authors. All authors read and approved the final manuscript.*

### **Article Information**

DOI: 10.9734/JAMMR/2021/v33i2331181

Editor(s):

(1) Dr. Emmanouil (Manolis) Magiorkinis, General Hospital for Chest Diseases "Sotiria", Greece.

Reviewers:

(1) Syed Shoeb Ahmad, ISH Hospital, India.

(2) José Luis García Serrano, University of Granada, Spain.

Complete Peer review History, details of the editor(s), Reviewers and additional Reviewers are available here:  
<https://www.sdiarticle5.com/review-history/77473>

**Case Report**

**Received 20 September 2021**

**Accepted 29 November 2021**

**Published 02 December 2021**

### **ABSTRACT**

A 40-year-old male factory worker presented to our eye clinic with left eye pain, redness and blurring of vision, associated with history of an injury sustained while hammering a nail into the wall three days ago. He had mild symptoms at the onset of the injury. Slit lamp examination of left eye showed a small, self-sealed laceration corneal wound at the temporal limbus and a smooth, well defined, oval mass on the iris in the anterior chamber in the lower temporal quadrant. Rest of the anterior segment and fundus were normal. X-ray orbits showed no intraocular foreign body in the left eye. In view of clinical suspicion, we proceeded with a CT scan of orbits which showed the presence of a small metallic foreign body in the anterior chamber of left eye. After giving topical antibiotic, cycloplegic, and corticosteroid eye drops along with systemic antibiotics for three days, we planned surgical removal of the mass in the anterior chamber. After the mass was removed, we noted a small metallic foreign body embedded within the fibrin mass. The same treatment was continued postoperatively. The left eye became white and quiet, and vision improved to 6/6 with above treatment. The key learning point presented is that when the history is suggestive of

intraocular foreign body, even though the X-ray orbits does not show the foreign body one has to get CT scan of orbits done to rule out its presence, especially when there is inflammatory mass in the anterior chamber as seen in our case.

**Keywords:** Foreign body in anterior chamber; inflammatory mass; metallic foreign body; radiology imaging.

## 1. INTRODUCTION

Ocular injuries predominantly affect the anterior segment of the eye. The intraocular foreign bodies (IOFB) are uncommonly seen in the anterior chamber when compared to vitreous and retina. They can cause perforating or penetrating open globe injuries. IOFB injuries vary in presentation, outcome, and visual prognosis depends on the location of injury, type and size of foreign body and the subsequent complications. Increased awareness about eye protection, improved surgical techniques, and advancements in bioengineering are responsible for an improved outcome in injuries with IOFB [1].

The foreign bodies in the eye are common amongst laborers who do not wear protective eyewear; 94% of patients presenting with IOFBs are males aged between 30 and 40 years. An IOFB can be categorized as metallic or non-metallic (organic or inorganic). Most of the traumatic IOFBs reside in the posterior segment (58%–88%), while the others are in the anterior chamber (10–15%) or the lens (2–8%). Metallic IOFBs, if left untreated, can result in direct mechanical damage and subsequent metallosis, such as ocular siderosis and chalcosis. However, the most serious complication is infectious endophthalmitis [2].

In a study of 64 perforating eye injuries with IOFBs treated over ten years were Lai [3] from Malaysia reported that population at risk were patients under 35 years (70%), males (95.3%) and work related (86%). Forty one (41) were seen in the posterior segment and 23 in the anterior segment. The most common cause of IOFB were hand hammer (64.1 %) followed by grass cutting (20.3%), machining (3.1%) and others (12.5). Greven et al [4] in their study of 59 patients undergoing removal of IOFB in USA, reported that hammering accounts for the majority (60–80%) of IOFBs, followed by power equipment or machinery (18–25%) and weapon-related injuries (19%).

It is imperative to perform a gonioscopic examination in all suspected patients of intraocular foreign bodies in the angle of anterior chamber, as they can be challenging to detect them [5]. All cases of IOFBs should be treated on emergency basis in view of potential danger of endophthalmitis. Long-term retained or misdiagnosed IOFBs may occur when patients do not pay attention or do not have access to medical care, but most patients will suffer from partial vision impairment or endophthalmitis.

We report a case of a small metallic foreign body in the anterior chamber presenting as an oval yellowish mass on the iris, in a factory worker following an injury to his left eye, highlighting the need to consider intra ocular foreign body despite atypical appearance.

## 2. CASE REPORT

A 40-year-old Bangladeshi factory worker presented with a two days history of a painful, watery left red eye, associated with blurring of vision. On further questioning, three days prior, he was hammering a nail and felt something entering into his left eye with speed. His symptoms initially were mild, improved after consulting a general practitioner who prescribed antibiotic eye drops. However, pain became severe with loss of vision the following day.

On examination Left eye: vision was 6/36, improving to 6/18 with pinhole. Slit-lamp examination revealed a self-sealed corneal laceration wound (1.5 x 2 mm) at the temporal limbus with minimal surrounding edema. A smooth, well defined, oval yellow mass (2.5 x 2.5 mm) was seen in the anterior chamber (4-5 o'clock position). It appeared to be on the surface of the iris, almost mimicking the appearance of an inflammatory mass (Fig. 1). There was aqueous flare and 3+ cells in the anterior chamber. Pupil was sluggish and mid-dilated with no relative afferent pupillary defect. The lens was clear. Intraocular pressure was 14 mmHg. Dilated pupil fundus examination was normal. Siedel's test was negative. Gonioscopy of left

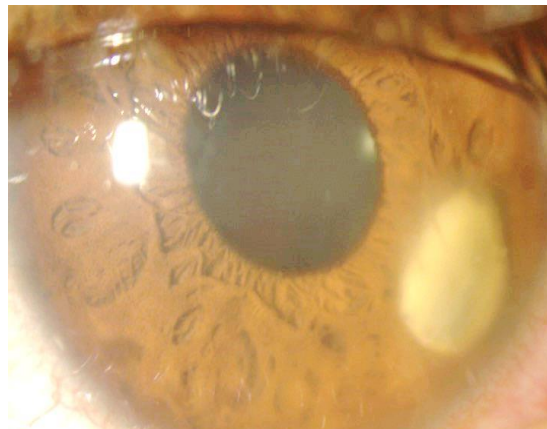
eye did not reveal any foreign body in the angle of anterior chamber.

Examination of the right eye: vision, anterior segment, fundus and intraocular pressure were normal. As the history indicated the possibility of a foreign body entering the left eye, a skull x-ray and B-scan were performed. However, no intraocular foreign body was visualized on the x-ray. B scan revealed no vitritis.

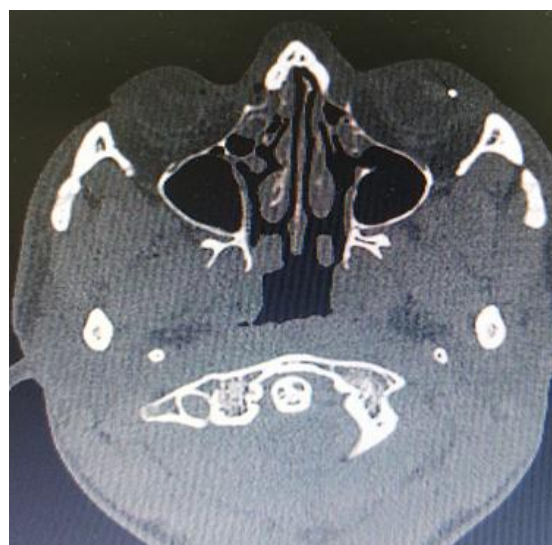The presence of flare and cells in the anterior chamber indicates inflammation in the eye. Therefore, the patient was started on topical eye drops -- homatropine 2% three times daily and predforte 1% four hourly daily in the left eye, under the cover of moxifloxacin 0.5% eye drops

one hourly and fortified ceftazidime 5% eye drops one hourly. Intravenous ciprofloxacin 400 mg two times daily was given in view of a yellowish mass in the anterior chamber over the iris.

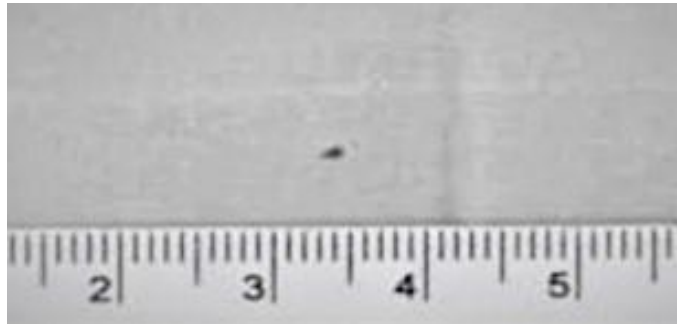
This atypical appearance of a mass in the anterior chamber, in combination with no intraocular foreign body seen on X-ray, proved to be diagnostically challenging. A CT scan of orbits was subsequently performed, which showed a small hyper dense radio-opaque area in the left anterior chamber (Fig. 2) suggestive of foreign body. The globe appeared intact. A final diagnosis of a metallic foreign body in the left anterior chamber was made.



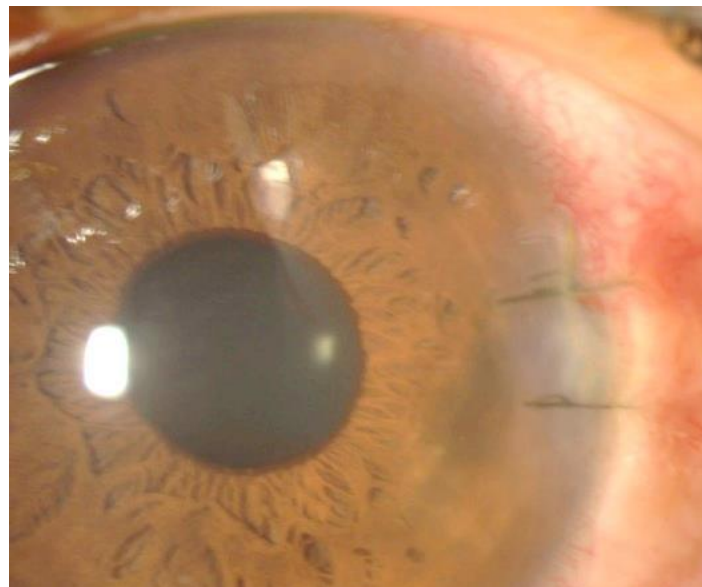
**Fig.1. showing the smooth, well defined, yellowish mass on the surface of iris, in the anterior chamber of the left eye**



**Fig. 2. Axial CT scan of orbits showing the hyper dense area (foreign body) in the anterior chamber of the left eye**



**Fig.3. Showing the removed metallic foreign body from the anterior chamber of the left eye**



**Fig. 4. Showing post-operative appearance of the left eye one week after discharge from the hospital**

Three days after the treatment, surgical removal of the mass was planned. Under sub Tenon's injections of xylocaine 2% anaesthesia, a corneal incision was made on the inner side of limbus from 3 - 4.30 clock position. Viscoelastic was injected into anterior chamber and the soft fibrin mass on the surface of iris was separated. It was removed using Kelman's forceps. The viscoelastic was washed and anterior chamber was formed with saline. The corneal wound was closed with 10-0 nylon sutures. Sub conjunctival injection of gentamicin 20 mg and dexamethasone 2 mg was given before patching the left eye. On opening the yellow mass, a small metallic foreign body (1.5 x 1 mm) was detected wrapped within the fibrin material (Fig. 3).

Post-operatively, moxifloxacin and fortified ceftazidime eye drops were reduced to two hourly; homatropine, and predforte were

continued. Cap. ciprofloxacin was given orally 500 mg twice daily for another four days. Vision on day one post-operatively improved to 6/9, with 2+ cells in the anterior chamber. One week after admission, vision remained stable in the left eye, with 1+ cells in the anterior chamber. Patient did not have any pain in the eye. The patient was discharged on topical moxifloxacin 4 hourly, predforte 4 hourly, homatropine once daily in the left eye.

In the follow up after one week, vision improved to 6/6 in the left eye. Slit lamp examination showed no flare and cells in the anterior chamber (Fig. 4). Moxifloxacin and predforte eye drops were reduced to q.i.d in the left eye for one week followed by t.d.s. for one week. Fortified ceftazidime and homatropine eye drops were stopped. He was advised to come after two weeks for checkup.

In the follow up examination, sutures at the limbus in the left eye were removed. Vision was maintained 6/6. Anterior segment, intraocular pressure and fundus were normal in the left eye. Moxifloxacin and predforte eye drops were reduced to once daily in the left eye for another one week only. Patient was advised to come for follow up if there is any problem in the left eye.

### 3. DISCUSSION

The anterior chamber foreign body should be removed through a surgical incision depending on the location and size of the foreign body. Usually a shelved incision slightly bigger than the size of the foreign body is created either in clear cornea or sclera to facilitate its easy removal. A 20-gauge rare earth magnet may retrieve the object through the surgical incision if it is metallic and small. Nonmagnetic objects or large magnetic objects are best managed with intraocular forceps. Use of viscoelastic will protect the tissues in the anterior chamber. Care should be taken while removing the foreign bodies to avoid any injury to surrounding tissue [1].

In the spectrum of ocular trauma, intraocular foreign bodies represent a potentially vision-threatening entity. The extent of injury often depends on four factors: the size and composition of the foreign body; the force at which the foreign body enters the eye; the location of the entrance wound; and the final resting place of the foreign body [5]. A retained anterior chamber foreign body can cause severe corneal endothelium injury, corneal edema, or even corneal decompensation because of long-term friction and can also stimulate pigmentation and uveitis [6].

Wen and Si [7] in their study of 165 patients of foreign bodies in the anterior chamber treated over 23 year in China, reported nonmetallic foreign bodies in 109 eyes, metallic foreign bodies (iron) in 55 eyes (33.3%) and unknown nature foreign bodies in 3 eyes. The foreign bodies were located on the surface of iris in 97 cases (58.8%) and at the anterior chamber angle in 40 cases. He suggested that in these patients, whenever combined procedures are required, it is better to remove the foreign bodies first and then perform the operation for complications.

A 31-year-old female with an asymptomatic metallic anterior chamber foreign body that was discovered 15 years after undiagnosed

penetrating ocular trauma was reported by He and Lv [8]. Asymptomatic anterior chamber foreign body has caused corneal endothelial injury and ocular siderosis, and that is why the metal particle embedded in the iris root in the lower part was removed in their patient.

In our case, the metallic foreign particle on the surface of iris surrounded by fibrin may have resulted due to severe inflammation in the anterior chamber causing an accelerated deposition of fibrin within a few days; thus triggering a diagnostic challenge due to atypical appearance of a foreign body. It was considered as an inflammatory mass in view of its position over the surface of iris and it was yellow looking. In addition, the X-ray of orbits did not reveal the metallic foreign body in the left eye. An iris cyst was another differential, hypothesised to be the result of a metallic foreign body penetrating the iris, without retention of the foreign body, but the colour of the mass and anterior chamber reaction were not in favour of it. However, in view of the self-sealed corneal laceration, and the patient's history, a CT scan of the orbits was subsequently performed which showed a metallic foreign body in the left eye. This diagnostic difficulty was also reported by Watts et.al [9], wherein a detached iris cyst was mistakenly believed to be a foreign body on the iris.

Mete et.al [10] reported a case of a missed metallic intraocular foreign body in the anterior chamber over a 2-year period without causing severe inflammatory reaction in a 42 year old man, who presented with symptoms and signs of uveitis later. In five o'clock meridian of the angle, an IOFB coated with hypopyon was observed under biomicroscopic magnification. Plain X-ray and computed tomography confirmed the foreign body in the left eye. After obtaining informed consent from the patient, the foreign body was removed under local anesthesia.

Imaging modalities available for detecting foreign bodies include plain film radiographs, computed tomography (CT), magnetic resonance imaging (MRI), and ultrasound. MRI and ultrasound modalities are useful for radiolucent objects (glass, wood, plastic, and organic objects such as thorns or spines [11].

As seen in this patient, the advantage of performing a CT scan is that it precisely helped to localize the site of the foreign body with its surrounding relationships [12]. However, as reported by Yeniad et al [13], even in the absence of intraocular foreign body noted on X-

ray and CT scan, a diagnosis of intraocular foreign body should not be ruled out in the presence of ocular trauma with evidence of inflammation. In our patient, the presentation of the thick fibrin seen gave a strong suspicion that there was a presence of intraocular retained foreign body, which encouraged us to proceed with a CT scan orbits to confirm it.

If the anterior segment optical coherent tomography facility is available, it will help to identify the presence of intraocular foreign bodies in the eye. Yang et.al [14] reported the glass pieces in the anterior chamber in a 30 year old male patient who was admitted with chemical injury in left eye recently. On slitlamp examination, a small piece of glass was found in the inferior anterior chamber in the same eye. On repeated questioning, he recalled that he was injured by an exploded light bulb around 21 years ago. He was asymptomatic until he saw "something moving" in front of the left eye one month ago. Computed tomography (CT) scanning, ultrasonography, ultrasound biomicroscopy (UBM), anterior segment optical coherence tomography (AS-OCT) verified the presence of multiple intraocular foreign bodies (IOFBs) in the anterior chamber and vitreous cavity.

On our patient, the foreign body was removed with forceps rather than magnet as the presence of thick fibrin material would have rendered the magnet ineffective. A newer method using encapsulation by an intraocular lens injector as proposed by Ishii et al [15] might have also been ineffective due to the presence of thick fibrin.

#### 4. CONCLUSION

This case highlights that the presenting clinical features of a foreign body in the anterior chamber can be varied and cannot be effectively ruled out until appropriate imaging is performed. In patients who present with a history suggestive of a penetrating trauma, a full workup and detailed imaging should always be considered even if the clinical features and initial X-ray imaging do not support an intraocular foreign body. These patients should be promptly diagnosed and appropriately managed for regaining normal vision, as seen in our patient.

#### CONSENT

The patient was admitted in the eye ward. Informed consent was taken for investigations and operation, if required.

#### ETHICAL APPROVAL

It is not applicable.

#### COMPETING INTERESTS

Authors have declared that no competing interests exist.

#### REFERENCES

1. Kamjoo S, Chhablani J. Intraocular Foreign Bodies (IOFB). Eye Wiki. Available: [https://eyewiki.org/Intraocular\\_Foreign\\_Bodies\\_\(IOFB\)](https://eyewiki.org/Intraocular_Foreign_Bodies_(IOFB)). (accessed on October 16, 2021)
2. Lai YK. Perforating eye injuries due to intraocular foreign bodies. *Med J Malaysia*. 1992;47(3): 212-19.
3. Loporchio D, Mulkamala L, Gorukanti K, et al. Intraocular foreign bodies: a review. *Surv Ophthalmol*. 2016;61:582-96.
4. Greven CM, Engelbrecht NE, Slusher MM, et al. Intraocular foreign bodies: Management, prognostic factors, and visual outcomes. *Ophthalmology*. 2000;107(3): 608-12.
5. Graffi S, Tiosano B, Cnaan RB et.al. Foreign Body Embedded in Anterior Chamber Angle. *Case reports in Ophthalmol Medicine*; 2012. Article ID 631728. DOI.10.1155/2012/631728.
6. Jastaneiah SS. Long-term corneal complication of retained anterior chamber angle foreign body. *Saudi J Ophthalmol*. 2010;24:105-8.
7. Wen Z, Si M. The analysis of foreign bodies in the anterior chamber in 165 cases. *Yan KeXueBao*. 1990;6(3-4):108-10. (article in Chinese)
8. He N, Lv Z. A rare asymptomatic metallic intraocular foreign body retained in the anterior chamber for 15years: A case report. *Medicine (Baltimore)*. 2021;100(25): e26470. DOI:10.1097/MD.00000000000026470
9. Watts MT, Rennie IG. Detached iris cyst presenting as an intraocular foreign body. *J Royal Soc Medicine*. 1991;84:172-173.
10. Mete G, Turgut Y, Osman A, Gülşen U, Hakan A. Anterior segment intraocular metallic foreign body causing chronic hypopyon uveitis. *J Ophthal Inflamm Infect*. 2011;1:85-87.
11. Campbell EA, Christopher D. Wilbert CD. Foreign body imaging. In: *StatPearls*

- [Internet]. Treasure Island (FL): StatPearls Publishing; 2021 (latest update May 7, 2021).
12. Pokhraj PS, Jigar JP, Mehta C, Narottam AP. Intraocular metallic foreign body: role of computed tomography. *J Clin Diag Res.* 2014;8(12):RD01-3. DOI:10.860/jcdr/2014/9949.5271.
  13. Yeniad B, Beginoglu M, Ozgun C. Missed intraocular foreign body masquerading as intraocular inflammation: two cases. *International Ophthalmology.* 2010;30(6): 713-716.
  14. Yang X, Liu C, Liu L, Zhang L. A missed diagnosis of multiple intraocular foreign bodies for 21 years. *Cont Lens Anterior Eye.* 2017;40(6):432-435.
  15. Ishii K, Nakanishi M, Akimoto M. Removal of intracamerall metallic foreign body by encapsulation with an intraocular lens injector. *J Cataract Refractive Surg.* 2015;41: 2605-2608.

---

© 2021 Arvinth et al.; This is an Open Access article distributed under the terms of the Creative Commons Attribution License (<http://creativecommons.org/licenses/by/4.0>), which permits unrestricted use, distribution, and reproduction in any medium, provided the original work is properly cited.

*Peer-review history:*  
*The peer review history for this paper can be accessed here:*  
<https://www.sdiarticle5.com/review-history/77473>