



# **Histological Evaluation of Brain Tissue in Dyslipidemic Rats Treated with Dietary Supplements Based on Amazonian Fruits**

**Matheus Vinícius de Souza Carneiro<sup>1</sup>, Ricardo de Queiroz Freitas<sup>1</sup>,  
Lucas Baltar Rodrigues<sup>1</sup>, Wenberger Lanza Daniel de Figueiredo<sup>2</sup>,  
Geane Antiques Lourenço<sup>3</sup>, José Fernando Marques Barcellos<sup>3</sup>,  
Adele Salomão-Oliveira<sup>4\*</sup> and Rosany Piccolotto Carvalho<sup>3</sup>**

<sup>1</sup>Federal University of Amazonas (FUA), Av. General Rodrigo Octavio Jordão Ramos, 1200, Manaus, AM, Brazil.

<sup>2</sup>University Nilton Lins (UNL), Av. Prof. Nilton Lins, 3259, Manaus, AM, Brazil.

<sup>3</sup>Physiological Science Department, Federal University of Amazonas (FUA), Av. General Rodrigo Octavio Jordão Ramos, 1200, Manaus, AM, Brazil.

<sup>4</sup>Multi-Institutional Biotechnology Program, Federal University of Amazonas (FUA), Av. General Rodrigo Octavio Jordão Ramos, 1200, Manaus, AM, Brazil.

## **Authors' contributions**

*This work was carried out in collaboration among all authors. All authors read and approved the final manuscript.*

## **Article Information**

DOI: 10.9734/EJMP/2021/v32i630399

### Editor(s):

(1) Dr. Prem K. Ramasamy, Brandeis University, USA.

(2) Prof. Marcello Iriti, Milan State University, Italy.

### Reviewers:

(1) E. Rotimi, Damilare, Landmark University, Nigeria.

(2) Daniel Armando Villarreal Portillo, Universidad de las Américas Puebla, México.

Complete Peer review History: <https://www.sdiarticle4.com/review-history/71051>

**Original Research Article**

**Received 25 May 2021**

**Accepted 29 July 2021**

**Published 09 August 2021**

## **ABSTRACT**

**Aims:** By using histological analysis, the study aims to evaluate the effect of a nutraceutical based on the Amazonian fruits of camu-camu (*Myrciaria dubia* (Kunth) Mc Vaugh), acai (*Euterpe precatoria* Mart.) and guarana (*Paullinia cupana*) on the brain tissue (hippocampus) of dyslipidemic rats.

**Methodology:** Preclinical trials were conducted using male and female rats (n=30) of the Wistar strain (*Rattus norvegicus*) that were randomly divided into five groups (G) (n=6). G1 was control,

\*Corresponding author: E-mail: [adelesalomao@gmail.com](mailto:adelesalomao@gmail.com);

G2 was induced to obesity with consumption of experimental feed (hypercaloric and hyperlipidic), G3 was induced to obesity with consumption of experimental feed and treated with simvastatin (50 mg/kg/day), and G4 and G5, which were induced to obesity with the consumption of experimental feed and supplemented with 100 mg/kg/day and 200 mg/kg/day of the formulation, respectively. The study period was 72 days, and, for 37 days, induction to obesity was performed with the experimental feed (hypercaloric and hyperlipidic). During the following weeks, for 35 days, after division of the groups, certain groups received, in parallel, treatment with simvastatin (G3) or supplementation with the nutraceutical (G4 and G5). Subsequently, histological slides of the brain tissue stained with violet cresyl were elaborated, photographed and analyzed.

**Results:** No significant differences were observed between the mean of intact neurons among the experimental groups induced to obesity. The neurotoxic effect, evidenced by the significant difference between the mean of intact neurons between the control group and obesity-induced groups, corroborates the findings of neuronal damage and degenerative processes reported in the literature.

**Conclusion:** The nutraceutical based on Amazonian fruits was not able to prevent the neurotoxic effect arising from the hyperlipidic and hypercaloric diet, and therefore did not present a neuroprotective effect in Wistar rats under the conditions established in the experiment.

*Keywords: Dyslipidemia; Amazonian fruits; obesity; nutraceutical; brain tissue.*

## 1. INTRODUCTION

The hippocampus, through its neuronal circuits and neuroendocrine mechanisms, plays an important role in the control of food intake, in addition to acting in the formation of new memories and spatial navigation [1]. Studies have shown a relationship between obesity and cognitive decline, as well as an association with the increased risk of neurodegenerative diseases such as Alzheimer's disease [2,3]. Cognitive dysfunction of the hippocampus associated with obesity is characterized by deficits in hippocampal-dependent learning and contextual memory processes and may precede, as well as promote, weight gain [4,5].

Being overweight is considered to have reached epidemic proportions, and it also causes the development of non-communicable diseases (NCDs) that have a high impact on global public health. In Brazil, being overweight affects 55.7% of the adult population, while adult obesity affects 19.8% [6]. Among children, this number is slightly lower and shows a general prevalence of 14.1% [7]. In the US, excess weight already affects 68.5% of the adult population, and recent data from the US National Health and Nutrition Survey from 2013 to 2016 found that obesity (defined as BMI  $\geq$  30 kg/m<sup>2</sup>) affects 41.1% of adult women and 36.6% of adult men [8]. Among young children and adolescents between 2 and 19 years of age, the prevalence was 18.5% between 2015 and 2016 [9].

To minimize this epidemic, studies have been carried out in the Amazon in search of alternative treatments, and the chemical and nutritional characteristics of the Amazonian fruits camu-camu (*Myrciaria dubia* (Kunth) McVaugh), acai (*E. precatoria* Mart.), and guarana (*Paullinia cupana*) have aroused interest due to their high content of bioactive compounds and antioxidants. These fruits also provide nutrients that are essential for proper organic functioning, since they have bioactive compounds such as ascorbic acid, phenolic compounds and methylxanthines, all of which have protective effects on the development and progression of dyslipidemia [10-14].

The studies of Napatsorn et al. [2] and Lizarbe et al. [15] demonstrate the degenerative and inflammatory effect in the hippocampus of rats and mice as a result of a long-term hyperlipid diet. The study of Napatsorn et al. [2] also found that after 40 weeks rats that had consumed a hyperlipid diet presented increased expression of apoptotic proteins accompanied by dendritic spine loss in the hippocampus. These changes were associated with increased levels of NTR1, PLCB-1 and PKC proteins in the brain. Lizarbe et al. [15] observed that mice provided with diets of 45% and 60% fat presented deterioration of the systems that are involved with neurotransmission and gliotransmission in the hippocampus, as well as presenting impaired spatial memory performance. The review by Yilan et al. [3] demonstrated that the inflammatory process in the hippocampus associated with obesity is characterized by

increased inflammatory factors such as IL-1 $\beta$ , IL-6 and TNF-alpha, activation of neuro-inflammatory pathways, increased neuronal apoptosis, decreases in neurogenesis, in synaptic formation and in long-term potentiation.

## 2. MATERIALS AND METHODS

### 2.1 Acquisition of the Nutritional Supplement

The nutraceutical containing the Amazonian fruits camu-camu (*Myrciaria dubia* (Kunth) Mc Vaugh), acai (*Euterpe precatoria* Mart.) and guarana (*Paullinia cupana*) was acquired in the form of a raw extract (RE) whose formulation is registered at the Brazilian National Institute of Industrial Property (INPI) under the process number BR 10 2018 068302 0.

### 2.2 Experimental Diet

In our study, the hypercaloric and hyperlipidic feed was used to feed the groups of experimental rats and its formula is registered at the National Institute of Industrial Property (INPI) under process number BR 10 2020 002474 4.

### 2.3 Animal Research Protocol

This study was submitted to and approved by the Ethics Committee on the Use of Animals (CEUA-INPA), certified under n $^{\circ}$  007/2017, and met the standards that establish the procedures for the scientific use of animals in Brazil. The rats (n=30) of the Wistar (*Rattus norvegicus*) lineage were males (Nm=15) and females (Nf=15), and were obtained from the INPA vivarium (National Institute for Amazonian Research, Amazonas state, Brazil). At 22 days of age, the young were weaned, acclimated for 4 days and housed randomly in polyethylene cages with autoclaved pine shavings, with controlled humidity and constant temperature and a light-dark cycle of 12 hours. The animals received water and commercial feed *ad libitum*. The water containers for the animals were replenished weekly while the food containers were filled daily and the leftovers of the feed were weighed and measured before each change to assess the intake [16]. The weight of the animals was monitored weekly using a semi-analytical scale.

### 2.4 Study Design

The study period was 72 days, during which for 37 days the induction of obesity was performed

with the experimental feed. After 37 days of induction of obesity through the administration of the experimental feed, each animal was housed in an individual cage and all the animals were randomly divided into one control group and four experimental groups with six rats in each group. During the following weeks, for 35 days, certain groups of animals received, in parallel, supplementation with the nutraceutical or treatment with simvastatin. All experimental groups continued to receive the experimental feed.

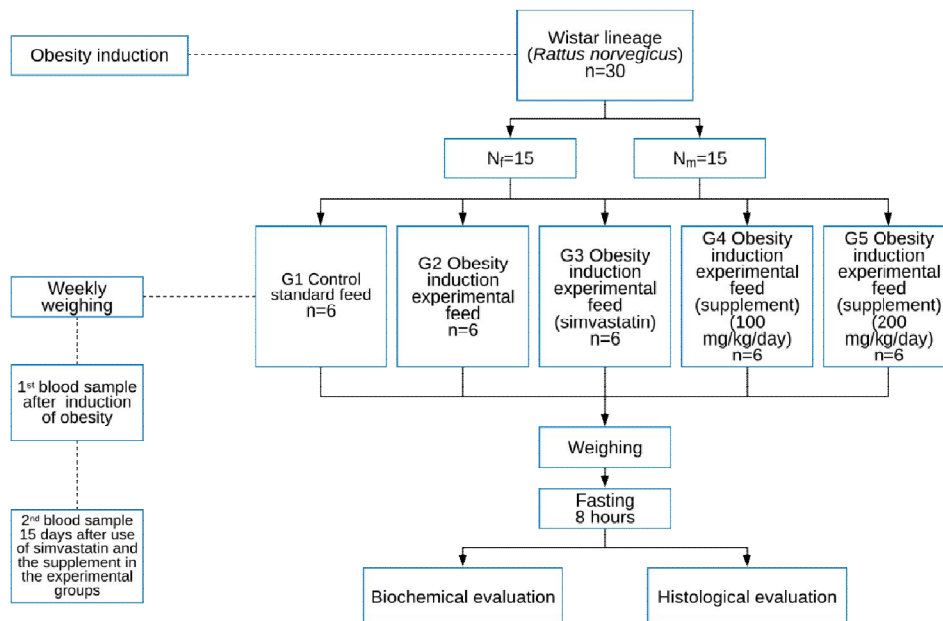
According to the experiment and analysis, these groups were identified as follows: Group 1 (G1) - control (balanced diet); Group 2 (G2) - induced to obesity through the experimental feed (hypercaloric and hyperlipidic); Group 3 (G3) - induced to obesity through the experimental feed and treated with simvastatin (50 mg/kg/day) [17]; Group 4 (G4) - induced to obesity through the experimental feed and supplemented with 100 mg/kg/day of the nutraceutical; and Group 5 (G5) - induced to obesity through the experimental feed and supplemented with 200 mg/kg/day of the nutraceutical (Fig. 1).

Physiological properties were observed after oral administration of the nutraceutical at doses of 20 mg and 40 mg/0.5 mL of the solution by gavage. Physical signs were observed daily according to an adopted protocol, which discriminated the behavior of fur, peripheral effects, stimulation and central depression, and recorded their presence in degrees of intensity or absence [18].

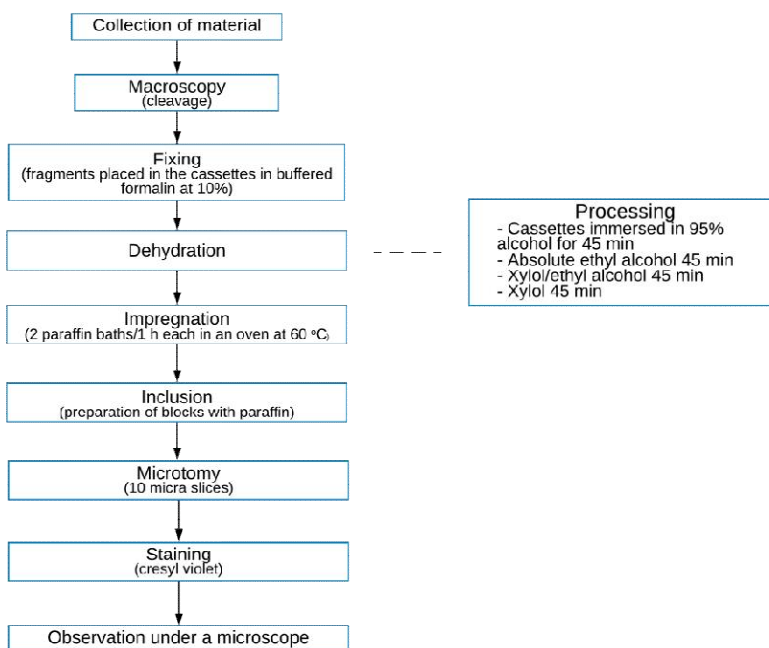
Before the end of the test, all animals were previously fasted for 8 hours to avoid possible interference in biochemical dosages. Afterwards, they were anesthetized with ketamine 0.5 mL/kg and xylasin 0.1 mL/kg, via intraperitoneal (IP) route, and were euthanized on the same day. The brains of the animals were removed and weighed immediately after euthanasia and then stored in 10% buffered formalin. For the histological analysis, the brains were stained with cresyl violet, according to the protocol adopted by the Laboratory of Functional Histology/UFAM for the stages of the histological techniques (Fig. 2).

To isolate the region corresponding to the hippocampus, coronal cuts of 10  $\mu$ m thickness were made with a semi-automatic rotary microtome (RM 2245, Leica Biosystems, Germany) and then the specimens were

processed and impregnated in paraffin to generate sections of the biological material. Subsequently, the cuts were placed on glass slides and stained with cresyl violet for visualization and analysis under optical microscopy.



**Fig. 1. Scheme of the preclinical study methodology**



**Fig. 2. Histological analysis schemes**

Histopathological evaluation of the organs involved the observation of possible microscopic lesions or cellular alterations such as neuron integrity or necrosis, respectively. Thus, histomorphometric analyses were performed using an image capture and analysis system, which consisted of a binocular microscope (DM500, Leica Microsystems, Switzerland) with an attached camera (ICC50 W, Leica Microsystems, Switzerland) [19]. The extent of neuronal injury in the acute phase of the model was evaluated to determine the neuro protective action of the nutraceutical under test by using histology techniques of brain tissue and counting of intact neurons in the hippocampal region.

## 2.5 Microbiological Analysis of Nutritional Supplement and Modified Feed

Microbiological analyses were performed in the Microbiology Laboratory/INPA with 10 g for the quantification of total coliforms, fecal coliforms and fungi (in triplicate) in compliance with the recommendations of the American Public Health Association (APHA) [20], as well as current Brazilian and international legislation [21,22].

## 2.6 Statistical Analysis

The results were analyzed by means of analysis of variance (ANOVA) using the F test, and mean comparison test using of the Student's t test, both at the probability level of 5%, and were

analyzed using the statistical program Minitab, version 14.

## 3. RESULTS AND DISCUSSION

### 3.1 Microbiological Analysis of the Supplement and Experimental Feed

Microbiological analyses showed acceptable results that were within the limits established by the Brazilian Health Regulatory Agency (Anvisa) (2001) for total coliforms, molds and yeasts, according to the recommendations of the American Public Health Association, APHA [20] and other current legislation [22]. The results of the microbiological count (Table 1) showed that the sanitizer (5% sodium hypochlorite) was effective in the elimination of pathogenic microorganisms and deteriorating elements, as well as all of the processing steps for the production of the raw extract (raw, pre-cleaning, cleaning, removal of pulp, freezing, and freeze-drying), and of the experimental feed (raw material, handling, and the time and temperature of the oven) and that hygiene and sanitary safety had been preserved.

### 3.2 Murinometric Analysis

Tables 2 and 3 below refer to the data of the murinometric measurements of the control and experimental groups, which showed no statistical difference ( $p \geq 0.05$ ) between the treatments. However, the group that received supplement 2 presented the lowest value in the evaluations.

**Table 1. Microbiological count in camu-camu, acai and guarana sanitized with 5% sodium hypochlorite for 10 min and the count for the prepared experimental feed**

5% sodium hypochlorite for 10 min			
	Total coliforms	Fecal coliforms	Fungi
Temperature (°C)	37	45	35
Time	24-48 h	24-48 h	5 days
MLN /g*	0.0	0.0	-
CFU /g**	-	-	<10

\* MLN- Most likely number, \*\* CFU – Colony forming unit

**Table 2. Descriptive statistics: Lee index (LI) versus treatment**

Variable	Treatment	N	Mean	Minimum	Median	Maximum
Lee index (LI)	Control	6	282.33±10.01 <sup>a</sup>	275.00	278.00	301.00
	Supplement 1	5	272.00±13.36 <sup>a</sup>	262.00	263.00	289.00
	Supplement 2	5	173.90±12.41 <sup>a</sup>	163.00	270.50	286.00
	Obesity	6	279.83±12.22 <sup>a</sup>	263.00	282.50	294.00
	Simvastatin	6	273.33±12.21 <sup>a</sup>	260.00	272.00	295.00

Values followed by the same letter do not differ according to the one-way ANOVA test followed by the F test ( $p \geq 0.05$ )

In Fig. 3 below, it can be observed that the average weekly consumption of the control and experimental groups did not differ significantly ( $p \geq 0.05$ ) between them, but that the experimental group that received supplement 2 (G5), at the highest concentration, showed a greater variation in their consumption of the experimental feed and in weight loss (Fig.4). The observed biological effect can be attributed to the biochemical composition of the nutraceutical, namely a high content of ascorbic acid and phenolic compounds, which are involved in the process of weight control [11,12,14].

During the study period (72 days), induction to obesity was performed for 37 days with the experimental feed. This was then administered in parallel for groups G4 and G5, in the form of an RE-based supplementation of Amazonian fruits, for 35 days. No macroscopic lesions were observed in the brains of the animals belonging

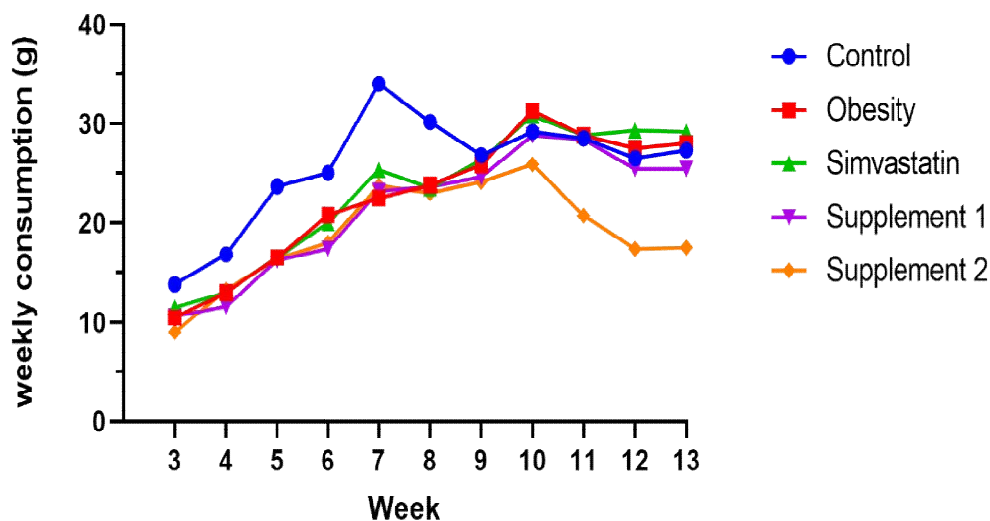
to the experimental groups. The mean brain weight showed no significant difference ( $p \geq 0.05$ ) between treatments. However, the group that consumed supplement 1 (100 mg/kg/day of the formulation) had the greatest weight variation among the groups (Fig. 5).

Histologically, the hippocampus is subdivided into four regions: Ammon's horn 1 (CA1), Ammon's horn 2 (CA2), Ammon's horn 3 (CA3) and the dentate gyrus (DG) [19]. The morphological alterations found include a reduction in neuronal cell size and a decrease in the dendritic ramifications in the pyramidal neurons. Fig. 6 shows that there was significant neuronal loss in the CA1 region in rats submitted to the hypercaloric and hyperlipidic diet (experimental groups) when compared to the control group. There was no significant difference  $p \geq 0.05$  between the number of intact neurons among the experimental groups (G2 to G5).

**Table 3. Descriptive statistics: waist circumference (WC) versus treatment**

Variable	Treatment	N	Mean	Minimum	Median	Maximum
CC (cm)	Control	6	20.67±2.25 <sup>a</sup>	18.00	20.50	23.00
	Supplement 1	5	19.60±3.13 <sup>a</sup>	17.00	18.00	23.00
	Supplement 2	5	12.25±2.38 <sup>a</sup>	10.00	16.50	22.00
	Obesity	6	21.00±2.53 <sup>a</sup>	18.00	21.50	24.00
	Simvastatin	6	21.00±3.69 <sup>a</sup>	17.00	21.00	25.00

Values followed by the same letter do not differ according to the one-way ANOVA test followed by the F test ( $p \geq 0.5$ )



**Fig. 3. Analysis of variance of weekly consumption (g) versus treatment. Values followed by the same letter do not differ according to the one-way ANOVA followed by the F test ( $p \geq 0.05$ )**

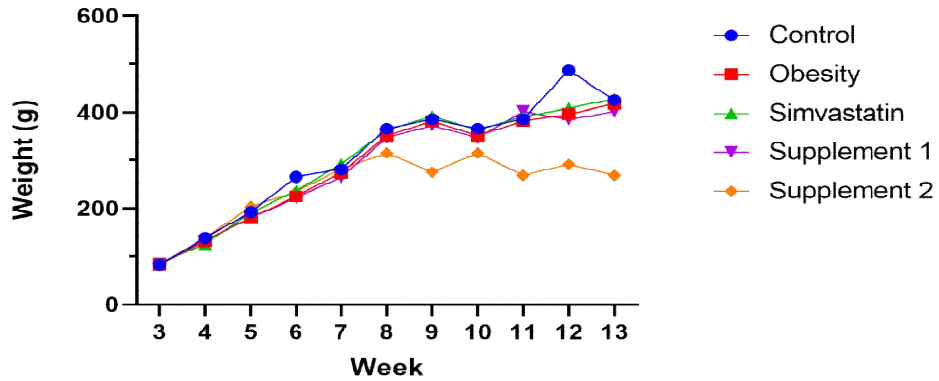


Fig. 4. Analysis of variance of weekly weight (g) versus treatment. Values followed by the same letter do not differ according to the one-way ANOVA followed by the F test ( $p \geq 0.05$ )

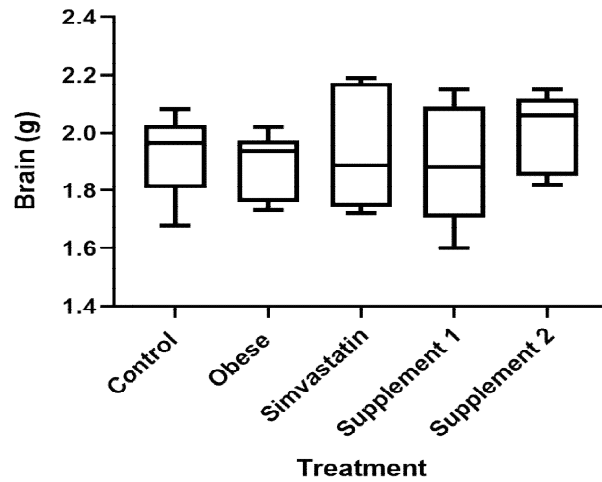


Fig. 5. The mean weights of the brains of the mice of the treatment groups G1 (control), G2 (obese), G3 (simvastatin), G4 (supplement 1) and G5 (supplement 2) do not differ from each other, when using the F test, in the one-way ANOVA ( $p \geq 0.05$ )

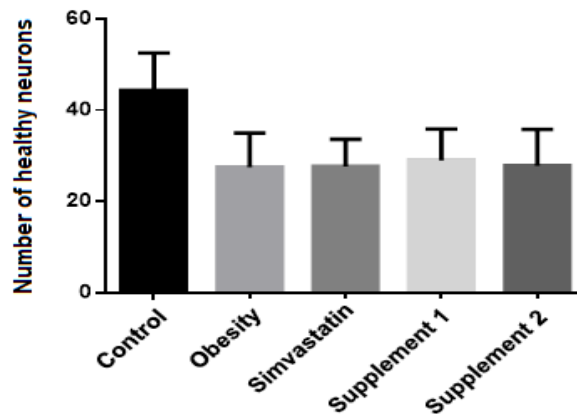
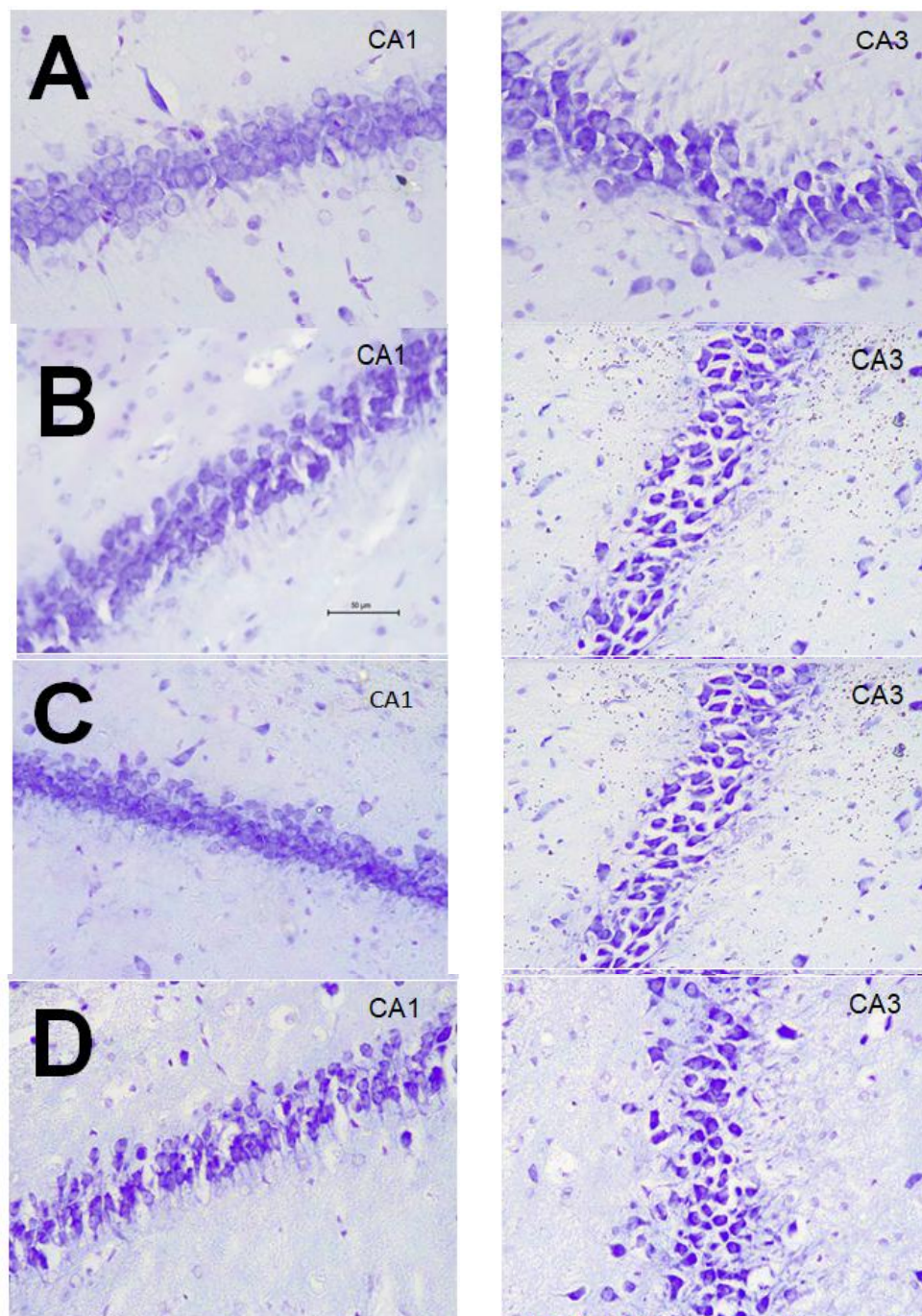


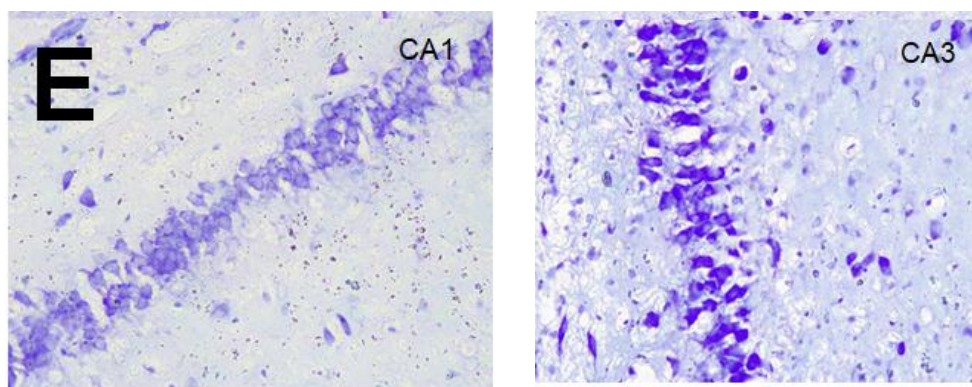
Fig. 6. Mean number of intact neurons in the experimental groups and control. Experimental groups do not differ from each other by the F test in the one-way ANOVA ( $p \geq 0.05$ )

The analysis of the hippocampal structure of the experimental animals in Fig. 7 shows the presence of pyknotic cells (with marked coloration, loss of nucleus shape and no defined nucleolus), and demonstrates the neuronal lesion in the hippocampus of the animals submitted to the hyperlipidic and hypercaloric diet

(experimental groups) compared to the group of animals that received a balanced diet (G1 - control). The count of the intact pyramidal cells of the CA1 region of the hippocampus reveals significant neuronal loss in the group of animals submitted to the hyperlipidic and hypercaloric diet, as can be observed in Fig. 6.







**Fig. 7. Photomicrography of the histological slices of the brains of the Wistar mice used in groups: G1 - control (A), G2 - induced to obesity without treatment (B), G3 - induced to obesity and treated with simvastatin (C), G4/G5 - induced to obesity and treated with the formulation in 100 and 200 mg/kg/day, respectively (D), histoarchitecture of the CA1 and CA3 regions of the control animals presented no alterations in the slides stained with cresyl violet (Nissl stain) (400x). In both CA1 and CA3, apoptotic pyramidal neurons and an area with disorganization of the glial network were observed. This cell death is evidenced by the intensification of the staining and the apparent spaces between neuronal bodies**

The treatments with simvastatin (G3 - simvastatin) or with the nutraceutical (G4 - supplement 1 and G5 - supplement 2) in the experiment did not prevent neuronal injury caused by the hyperlipidic and hypercaloric diet, and the injury in these groups was similar to that found in the obese group without treatment (G2 - obesity). Despite the high antioxidant content that makes up the nutraceutical under study, it was unable to prevent neurodegeneration promoted by the lipid and glycemic imbalance in the neuronal tissue of animals.

The studies of Napatsorn et al. [2] Yilan et al. [3], Alexis [5] and Lizarbe et al. [15] show the neuronal damage and/or pro-inflammatory effects or inflammatory state as a result of hyperlipidic/hypercaloric diets and metabolic disorders such as obesity and dyslipidemia. The results of this study showed the neuronal damage in the hippocampus in rats submitted to the hypercaloric and hyperlipidic diet, which corroborates with the findings in the literature regarding the neurodegenerative effect of the aforementioned conditions.

Due to the systemic and neurodegenerative problems arising from obesity, dyslipidemia, diabetes mellitus (DM) and metabolic syndrome (MS), several studies have observed the effect of bioactive compounds in rats submitted to high-calorie diets as experimental models. The biological effects in the experimental models were verified through studies with plant extracts

(*Prosthechea karwinskii* [23], herbal extracts T1, T2 and T3 [24], *Prosopis cineraria* [25], *Plantago albicans* [26], as well as the use of *Pinus* sp. mushrooms. [27], high flaxseed oil supplementation [28] and sapucaia nut supplementation (*Lecythis pisonis*) [29].

The study by Alejandra et al. [23] showed that the extracts of the pseudobulb (P), leaves (L) and flowers (F) of *P. karwinskii* significantly decreased ( $p < 0.05$ ) body fat, fasting glucose levels, cholesterol levels and triglycerides (TG) in Wistar rats. In relation to the antioxidant activity of the extracts evaluated by the DPPH method and the antioxidant capacity by the antioxidant activity index (AAI), extract L presented higher antioxidant capacity (AAI=5.7), followed by extract F (AAI=1.276) and extract P (AAI=0.925). However, possible neuronal damage to the hippocampus in the rats submitted to the hypercaloric and hyperlipidic diet was not verified in this study. In relation to the herbal extracts T1, T2 and T3, in Wistar rats, a significant decrease ( $p < 0.05$ ) was observed in plasma levels of TG, total cholesterol and LDL-C, as well as in fat deposition in rats submitted to high-fat diet (HFD) that received T1 and T3 supplementation. Nevertheless, there was no improvement in lipid profile in the rats that received T2 extract with herbal compounds [24].

In the study in which extracts of the fruit *P. cineraria* were used, and which were administered in Sprague-Dawley rats that were

divided into 12 groups, significant inhibition ( $p < 0.05$ ) of the alterations caused by the high-fat diet was noted. Such inhibition was observed in TG, HDL-C, LDL-C and VLDL-C, and it can be noted that the LDL/HDL ratio and the atherogenic index were significantly reduced ( $p < 0.01$  and  $p < 0.001$ ) [25]. Another study used a water-based extract from the medicinal plant *P. albicans* to treat male Wistar rats, and the results showed that the body weight and the relative weight of the adipose tissue in the group treated with the extract were significantly lower ( $p < 0.05$ ) when compared with the untreated group. The study also showed that the group administered with *P. albicans* presented a significant decrease ( $p < 0.05$ ) in serum levels of triglycerides, total cholesterol, and LDL-C, and a significant increase in HDL-C. As for the antioxidant capacity of the formulation,  $EC_{50} = 250 \pm 2.12$   $\mu\text{g/mL}$  was obtained in the DPPH test and  $EC_{50} = 27.77 \pm 0.14$   $\mu\text{g/mL}$  in the FRAP test [26].

The comparative study between different doses of flaxseed oil conducted with 40 male Wistar rats with acute dyslipidemia induced by Triton WR 1339 at a dose of 400 mg/kg body weight were divided into control group (G1) and 4 test groups (G2, G3, G4, G5) with 8 animals each. The test groups received varying amounts of flaxseed oil corresponding to 50 mg/kg (G2), 100 mg/kg (G3), 500 mg/kg (G4) and 750 mg/kg (G5). Despite the significant results for the G2 group, which presented anti-lipid-lowering properties for triglycerides, glycemia and cholesterol compared to the control group, the experiment did not show sufficient improvement to reach normal levels in the groups of the experiment for any of the parameters presented (TG, glucose and cholesterol) [28].

In the study that evaluated the effects of the diet supplemented with *Pinus* sp. sawdust along with the mycelium of *Pycnoporus sanguineus* in the metabolism of diabetic rats, a significant decrease ( $p < 0.05$ ) in serum levels of total cholesterol, non-HDL cholesterol and TG was observed in groups of rats treated with supplemented feed. However, it was found that in the group of diabetic animals treated with diet supplemented with *Pinus* sp. sawdust, separately, there was a significant increase ( $p < 0.05$ ) in HDL cholesterol levels [27].

The studies of Alejandra et al., Mei-Yin et al. Pankaj and Sanjay, Giovana and Rui et al. were restricted to biochemical analyses [23-28]. Noura et al. [26] conducted biochemical analysis and

antioxidant tests. As such, the aforementioned studies did not verify possible neuronal damage in the hippocampus of rats submitted to hyperlipidic and hypercaloric diets, which made it impossible to identify or evaluate the existence of the neuroprotective effect of the biological compounds tested.

However, from the studies verified, *L. pisonis* is noted for having a neuroprotective effect in Wistar rats submitted to a high-fat diet [29]. It was observed though that Wistar rats on a diet supplemented with *L. pisonis* showed a lower gene expression ( $p < 0.05$ ) of inflammatory markers (NFkB (p65) and TNF- $\alpha$ ), and a higher expression ( $p < 0.05$ ) of the protein HSP-72 (which has an anti-inflammatory effect under conditions of metabolic stress) and the enzyme ZnSOD, both proteins involved in the anti-inflammatory and antioxidant response of the brain. Regarding antioxidant activity, there was a significant decrease ( $p < 0.05$ ) in the concentration of MDA (TBARS) and a significant increase ( $p < 0.05$ ) in the antioxidant enzyme activity expressed in SOD in rats on a diet supplemented with *L. pisonis*. The observed biological effects can be attributed to metabolic interactions of phenolic compounds, tocopherol, unsaturated fatty acids, magnesium, manganese, selenium, copper, iron and zinc, which are some of the components identified in studies on the chemical composition of *L. pisonis* [29]. Thus, among the studies evaluated, only the study of Marcos et al. [29] positively demonstrated the action of supplementation with *L. pisonis* and its neuroprotective effect (anti-inflammatory and anti-oxidant effect) in rats subjected to the consumption of a hyperlipidic diet.

The biochemical composition of the nutraceutical based on Amazonian fruits has a high content of ascorbic acid and phenolic compounds, and presents hypolipidemic effects and involvement in weight control, which are important for protection from the harmful effects of dyslipidemia arising from hypercaloric and hyperlipidic diets. However, the nutraceutical was not able to protect hippocampal tissue from lipid neurodegeneration under the conditions established in the present study.

#### 4. CONCLUSION

Despite the high antioxidant content of the nutraceutical formulation, it was not able to reduce neuronal damage resulting from the hypercaloric and hyperlipidic diet in the Wistar

rats under the conditions established in the study, as the neural damage was verified, and evaluated by the average of intact neurons in the groups induced to obesity. However, studies that used biochemical analysis and antioxidant activity tests have shown a significant decrease in body fat, fasting glucose levels, lipid profile and a significant increase in HDL-c in obesity-induced Wistar rats that received the nutraceutical. In these same groups, it was found that the LDL/HDL ratio and the atherogenic index were significantly reduced. Therefore, the use of nutraceuticals were able to present significant lipid-lowering and anti-inflammatory properties when compared to the control group, which suggests that future studies should be carried out in humans.

### DISCLAIMER

The products used for this research are commonly and predominantly use products in our area of research and country. There is absolutely no conflict of interest between the authors and producers of the products because we do not intend to use these products as an avenue for any litigation but for the advancement of knowledge. Also, the research was not funded by the producing company rather it was funded by personal efforts of the authors.

### CONSENT

It is not applicable.

### ETHICAL APPROVAL

The study protocol was submitted to and approved by the Ethics Committee on the Use of Animals (CEUA-INPA), certified under No. 007/2017, and met the standards that establish the procedures for the scientific use of animals in Brazil.

### ACKNOWLEDGEMENTS

We wish to express our gratitude to Dr. Adele Salomão de Oliveira for authorizing the publication of the results of her study (Table 1 to 3 and Figures 1 and 6) and the Masters student Maria Beatriz Tavares da Costa for her contributions to this study.

### COMPETING INTERESTS

Authors have declared that no competing interests exist.

### REFERENCES

1. Victor RS, Igor SM, Amanda LDP, Olagide WC. Life and death in the hippocampus: What's bad?. *Epilepsy Behav*; 2019. DOI:10.1016/j.yebeh.2019/106595.(In press)
2. Napatsorn S, Titikorn C, Dillon P, Kanokphong S, Pansa P, Nattayaporn A et al. Gut dysbiosis develops before metabolic disturbance and cognitive decline in high-fat diet-induced obese condition. *Nutrition*. 2020;69. DOI: 10.1016/j.nut.2019.110576.
3. Yilan L, Jing Y, Yan-Chuan S, Yi Z, Shu L. The role of inflammation and endoplasmic reticulum stress in obesity-related cognitive impairment. *Life Sci*. 2019;15;233:116707. DOI: 10.1016/j.lfs.2019.116707.
4. Terry LD, Sara LH, Susan ES, Camille HS, Xue F, Kimberly PK, Wei Z. Interrelationships among diet, obesity and hippocampal-dependent cognitive function. *J. Neuroscience*. 2013;253:110-122. DOI: 10.1016/j.neuroscience.2013.08.044.
5. Alexis MS. Models and mechanisms for hippocampal dysfunction in obesity and diabetes. *J. Neuroscience*. 2015;309:125–139. DOI: 10.1016/j.neuroscience.2015.04.045.
6. Anonymous. *Vigitel Brasil 2018: vigilância de fatores de risco e proteção para doenças crônicas por inquérito telefônico: estimativas sobre frequência e distribuição sociodemográfica de fatores de risco e proteção para doenças crônicas nas capitais dos 26 estados brasileiros e no Distrito Federal em 2018*. Ministério da Saúde; 2019. Accessed 20 February 2020. Available: <https://portalarquivos2.saude.gov.br/images/pdf/2019/julho/25/vigitel-brasil-2018.pdf>.
7. Ana MA, Luane MM, Máira SN, Anderson SS, Altacílio N. Prevalence of obesity in children and adolescents in Brazil: a meta-analysis of cross-sectional studies. *Curr Pediatr Rev*. 2015;11:36-42. DOI:10.2174/1573396311666150501003250.
8. Craig MH, Cheryl DF, Margaret DC, David SF, Cynthia LO. Trends in obesity and severe obesity prevalence in us youth and adults by sex and age, 2007-2008 to 2015-2016. *JAMA*. 2018a;319:1723–1725. DOI:10.1001/jama.2018.3060.

9. Craig MH, Cheryl DF, Margaret DC, David SF, Yutaka A, Cynthia LO. Differences in Obesity Prevalence by Demographic Characteristics and Urbanization Level Among Adults in the United States, 2013-2016. *JAMA*. 2018b;319(23):2419-2429. DOI: 10.1001/jama.2018.7270.
10. Adele S-O, Helyde AM. Bioactive Compounds and Antioxidant Activity of Camu-Camu (*Myrciaria dubia* (Kunth) Mc Vaugh) Grown on a Non-Flooded Land Ecosystem. *J. Food Nutr. Res.* 2017; 5: 941-946. DOI:10.12691/jfnr-5-12-10.
11. Adele S-O, Emerson SL, Helyde AM, Rosany PC. Benefits and Effectiveness of Using Paullinia cupana: A Review Article. *J. Food Nutr. Res.* 2018a;6:497-503. DOI:10.12691/jfnr-6-8-2.
12. Adele S-O, Suely SC, Helyde AM. Metabolic syndrome: Intake of Camu-Camu (*Myrciaria dubia* (Kunth) McVaugh). *Int. J. Food Sci. Nutr.* 2018b;3:5-13.
13. Paul CL, Joseph VP, Robert T, Caroline R. Antioxidant and Associated Capacities of Camu Camu (*Myrciaria dubia*): A Systematic Review. *J Altern Complement Med.* 2015;21:8-14. DOI: 10.1089/acm.2014.0130
14. Klenicy KLY, Luiz FRP, Carlos VL, Emerson SL, Valdir FV-J. Amazon acai: Chemistry and biological activities: A review. *Food Chem.* 2015;179:137–151. DOI:10.1016/j.foodchem.2015.01.055.
15. Lizarbe B, Soares AF, Larsson S, Duarte JMN. Neurochemical Modifications in the Hippocampus, Cortex and Hypothalamus of Mice Exposed to Long-Term High-Fat Diet. *Front Neurosci.* 2019;12:985. DOI: 10.3389/fnins.2018.00985.
16. Ozanildo VN, Ana PAB, Lucia KOY, Emerson SL. Effects of diet supplementation with camu-camu (*Myrciaria dubia* HBK McVaugh) fruit in a rat model of diet-induced obesity. *Na Acad Bras Cienc.* 2013;85:355-363. DOI: 10.1590/S0001-37652013005000001.
17. Ming L, Yu-hong J, Tiao-hong L, Lin-hui S, Bao-qi Z. Effect of simvastatin on atherosclerosis and central aortic pressure in ApoE gene knockout mice. *Zhejiang Da Xue Xue Bao Yi Xue Ban.* 2014;43(3):293-298. Chinese. DOI:10.3785/j.issn.1008-9292.2014.05.006.
18. Elisaldo AC, Fulvio RM. Protocolos em psicofarmacologia comportamental: um guia para a pesquisa de drogas com ação sobre o SNC, com ênfase nas plantas medicinais. 1th ed. São Paulo: Unifesp. Portuguese; 2011.
19. George P, Charles W. The rat brain in stereotaxic coordinates. San Diego: Academic Press; 1998.
20. Don FS, Carl V. Compendium of methods for the microbiological examination of foods. 3th. ed., Washington, DC: APHA; 1992.
21. Agência Nacional de Vigilância Sanitária (BRASIL). Resolução RDC nº 12, de 02 de janeiro de 2001. Regulamento técnico sobre padrões microbiológicos para alimentos. Diário Oficial da União 10 de janeiro de; 2001. Accessed 20 February 2020. Available:<https://www.gov.br/agricultura/pt-br/assuntos/inspecao/produtos-vegetal/legislacao-1/biblioteca-de-normas-vinhos-e-bebidas/resolucao-rdc-no-12-de-2-de-jan-10-de-2001.pdf>
22. International Commission on Microbiological. Microorganisms In Foods: Volume One: Their significance and methods of enumeration. 2th ed. University of Toronto Press; 1978.
23. Alejandra R-O, Rodolfo S-G, Alfonso A-A, Manuel J-E, Stefan Z-H, Luicita L-R. Effect of *Prosthechea karwinskii* (Orchidaceae) on obesity and dyslipidemia in Wistar rats. *Alexandria J. Med.* 2017;53:311–315. DOI:10.1016/j.ajme.2016.11.004.
24. Mei-Yin C, Yu-Hua K, Jin-Ming C, Chih-Min Y, Chao-Hsiang C. Effects of herbal mixture extracts on obesity in rats fed a high-fat diet. *J Food Drug Anal.* 2016;24: 594–601. DOI:10.1016/j.jfda.2016.01.012.
25. Pankaj GJ, Sanjay JS. Evaluation of Anti-Hyperlipidemic Potential of *Prosopis cineraria* Extract Against High Fat Diet Induced Hyperlipidemia in Laboratory Rat. *Pharmacologia. Sci Alert.* 2016;7:44-52. DOI: 10.5567/pharmacologia.2016.44.52.
26. Noura S, Amani E, Hafsia B, Sana N, Abdelfattah E, Najla H. Beneficial effects of *Plantago albicans* on high-fat diet-induced obesity in rats. *Biomed. Pharmacother.* 2016;84:1768–1775. DOI: 10.1016/j.biopha.2016.10.105.
27. Giovana R. Efeitos de dieta suplementada com serragem de *Pinus* sp. miceliada com *Pycnoporus sanguineus* sobre o metabolismo de ratos diabéticos. (Master of Sciences dissertation), University of Caxias do Sul, Brazil. Portuguese; 2017.

28. Rui GME, Carlos AM-F, Augusto CFM, Elaine CAG, Roberto KNC. Efeito de diferentes doses de óleo de linhaça no tratamento da dislipidemia em ratos. RBNE. 2012;6:336-342. Portuguese.
29. Marcos VM, Izabela MMC, Mônica MMC, Renata CLT, Antônio AX, José HQ. Neuroprotective effect of Sapucaia nuts (*Lecythis pisonis*) on rats fed with high-fat diet. Nutr Hosp. 2016; 33:1424–1429. DOI:10.20960/nh.805

© 2021 Carneiro et al.; This is an Open Access article distributed under the terms of the Creative Commons Attribution License (<http://creativecommons.org/licenses/by/4.0>), which permits unrestricted use, distribution, and reproduction in any medium, provided the original work is properly cited.

*Peer-review history:*

*The peer review history for this paper can be accessed here:*  
<https://www.sdiarticle4.com/review-history/71051>