



A Rare Case Study Biliary Cystadenoma: Management and Review of Literature

Mohammad Shoeb ^{a++*}, Madhura Killedar ^{a#}
and Sudhanwa Pathak ^{bt}

^a Department of General Surgery, Bharati Vidyapeeth (Deemed to be University) Medical College and Hospital, Sangli, India.

^b Bharati Vidyapeeth (Deemed to be University) Medical College and Hospital, Sangli, India.

Authors' contributions

This work was carried out in collaboration among all authors. All authors read and approved the final manuscript.

Article Information

Open Peer Review History:

This journal follows the Advanced Open Peer Review policy. Identity of the Reviewers, Editor(s) and additional Reviewers, peer review comments, different versions of the manuscript, comments of the editors, etc are available here: <https://www.sdiarticle5.com/review-history/112801>

Case Study

Received: 21/12/2023

Accepted: 26/02/2024

Published: 05/03/2024

ABSTRACT

This case reports the obstructive jaundice and cholangitis correlate with malignant disease and typically occurs with extra hepatic biliary cystadenoma. A 50 years non-alcoholic, post-menopausal female patient presented to OPD with itching all over the body for 3 months. She had colicky type of pain in upper abdomen from last 7 days. ERCP with stenting was done and planned for definitive surgery. CBD exploration done, cystic growth noted in CBD extending till confluence of ducts, growth removal done. Sent for histopathological examination with came to be biliary cystadenoma. Post operatively no complications were developed.

⁺⁺ Junior Resident;

[#] Professor and HOU;

[†] Consultant GI Surgeon;

^{*}Corresponding author: E-mail: mohammadshoeb7385@gmail.com;

Epithelial cells that line the gall bladder or bile ducts are the source of biliary cystadenoma. These cells are multiloculated and multiseptated. Another method is enucleation which is Recommended in cases where the tumour size and positioning makes resection unachievable.

Keywords: Biliary cystadenomas; tumour epithelial cells; hepatobiliary stem cells.

ABBREVIATIONS

CBD : Common Bile Duct
USG : Ultra sonogram
MRCP : Magnetic Resonance Cholangiopancreatography
MRI : Magnetic Resonance Imaging
LFT : Liver Function Test
AFP : Alpha Fetoprotein
CEA : Carcinoembryonic Antigen
ERCP : Endoscopic Retrograde Cholangiopancreatoy

1. INTRODUCTION

Less than 5% of liver cysts that are non-parasitic are caused by biliary cystadenoma [1]. More often originate from primary biliary system or from the aberrant bile duct [1,2,3]. Fewer are extra hepatic [2,4,5] and most are intrahepatic (85%) [2,6-9]. They sporadically appear to originate from the gallbladder. Clinically and radiologically, it is challenging to determine between biliary cystadenoma and biliary cyst adenocarcinomas, so surgery to be taken into consideration.

At the time of diagnosis, most of the patients are middle aged women with an average age of 45. The majority of the symptoms such as Epigastric and right upper quadrant pain, jaundice, cholangitis are caused by mass effects [1,10].

Obstructive jaundice and cholangitis are uncommon, do not occur with malignant illness and are often associated with extra hepatic cystadenoma.

2. CASE PRESENTATION

50 years non-alcoholic, post-menopausal female patient presented to OPD with itching all over the body for 3 months she had collected type of pain in upper abdomen from last 7 days. No history of Melena, weight loss or fever.

Serum amylase, lipase and routine blood reports were normal. Serum bilirubin total: 10.2, Direct bilirubin: 8.3, Indirect bilirubin: 1.9 Alkaline phosphatase: 491.

USG (ultrasonogram) suggestive of dilated intrahepatic ducts with dilated common bile duct (CBD) with hypoechoic growth within, prompting further imaging. So, contract CT (computed tomography) was done, suggestive of multiseptated cystic lesion in CBD, common hepatic ducts and left hepatic duct. Dilated CBD measures 12 mm. Mild thickening of CBD with small focal heterogenous enhancement at papilla? infective? Neoplastic aetiology needs further co relation. So MRCP (magnetic resonance *Cholangiopancreatography*) done and findings shown in Fig. 1.

So, after consulting with GI surgeon, the first step was to perform an ERCP (endoscopic retrograde cholangiopancreatoy) with stenting to relieve obstructive jaundice, followed by definitive surgery. ERCP with stenting was completed with 7 French plastic catheter.

To rule out malignancy, tumor markers CEA- (carcinoembryonic antigen), AFP (alpha fetoprotein) and CA 19-9 were sent, the results were normal, and the patient was scheduled for surgery.

MRCP:

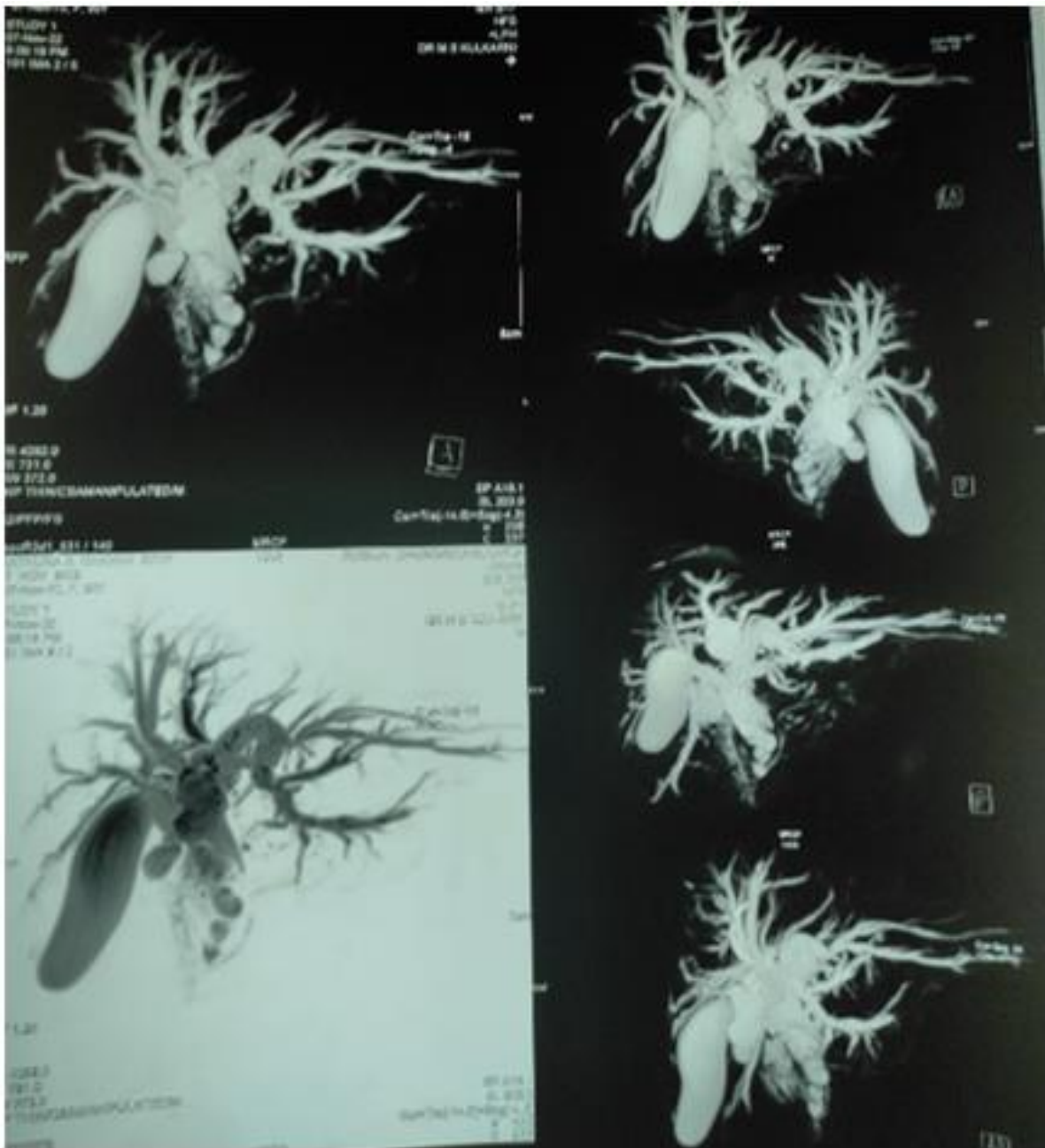

Fig. 1. MRCP showing:

- **Fusiform enlargement of entire CBD, more in supra-pancreatic region.**
 - **Dilated CBD, Right and left hepatic duct.**
- **Multi septate, cystic morphology, filling and distending CBD as well as common hepatic duct? Possibility of cystic neoplastic lesion.**

3. INTRAOPERATIVE FINDINGS

Kocher's incision was performed. Distended gall bladder noted with enlarged peri-choledochal lymph nodes. Lymph nodes were sent for frozen

section, which was suggestive of reactive lymphadenitis. Cystic growth was palpable in CBD with extending to common hepatic duct. Intraoperative cholangiogram was performed to locate cystic growth (as shown in Fig. 2).

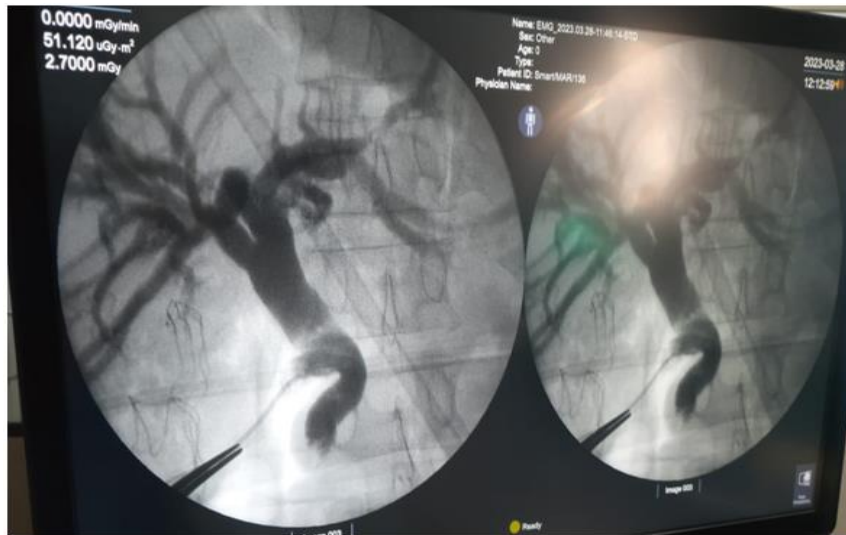


Fig. 2. Intraoperative cholangiogram delineating the cystic growth extending from intra hepatic ducts to CBD with filling defect

CBD exploration done; cystic lesion detected in CBD extending from intra hepatic ducts to second portion of CBD. Stent in CBD noted with normal distal part of CBD.

4. CBD EXPLORATION AND REMOVAL OF LESION

After CBD exploration, 7*2cm cystic lesion extending from CBD to confluence of hepatic

duct removed (As shown in Fig. 3) and send for histopathological examination. CBD patency was confirmed after removing cystic growth. CBD closure done with polyglactin 3.0. Cholecystectomy done on same setting. Excised specimen shown in Fig. 4. Histopathological slides shown in Figs. 5 and 6.

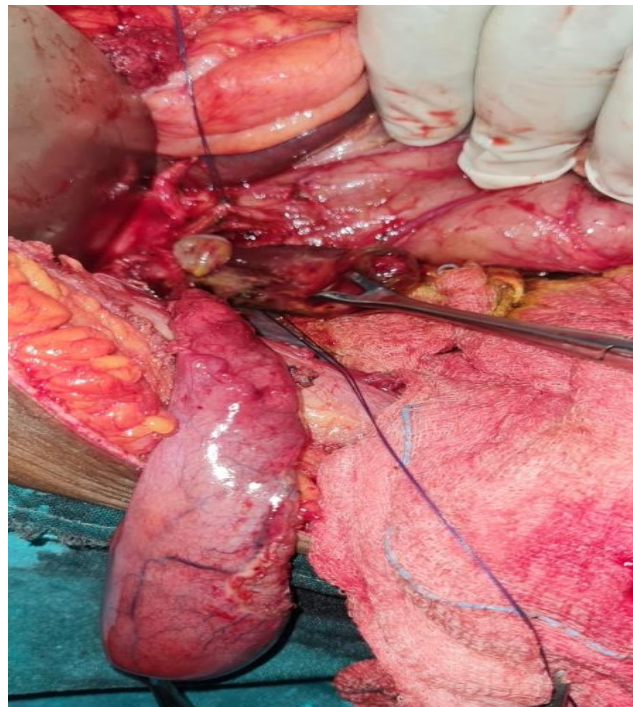


Fig. 3. CBD exploration with removal of cystic lesion

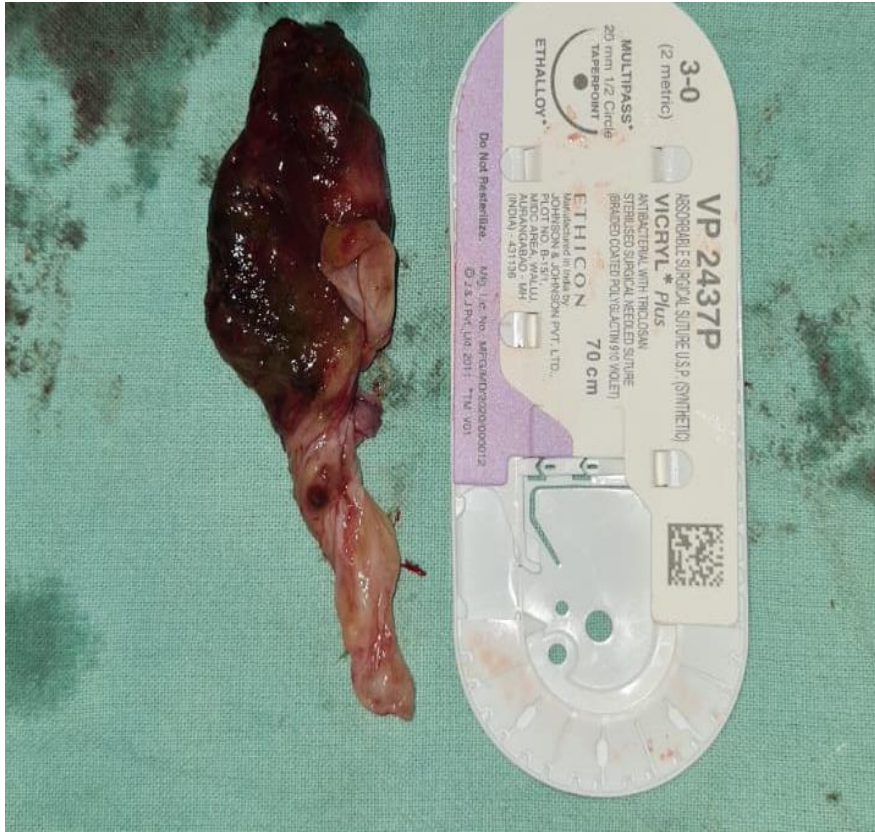

Fig. 4. Excised specimen

Histopathological slides:

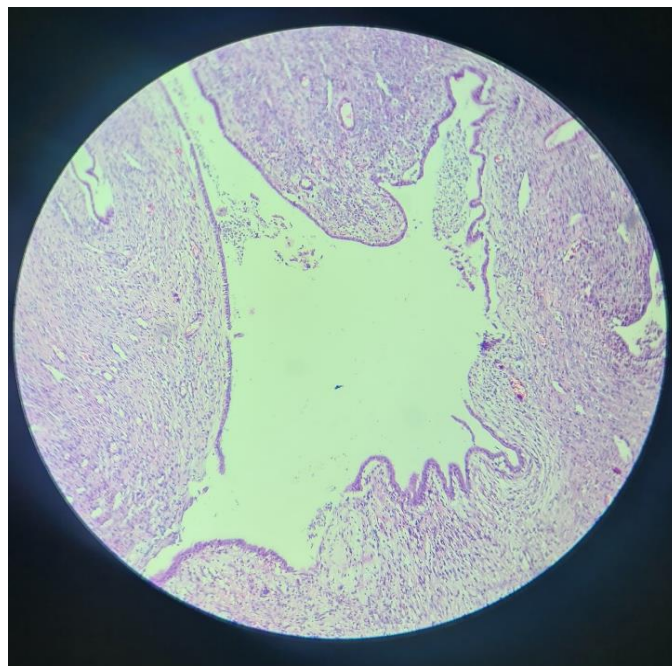


Fig. 5. 10x view of biliary cystadenoma

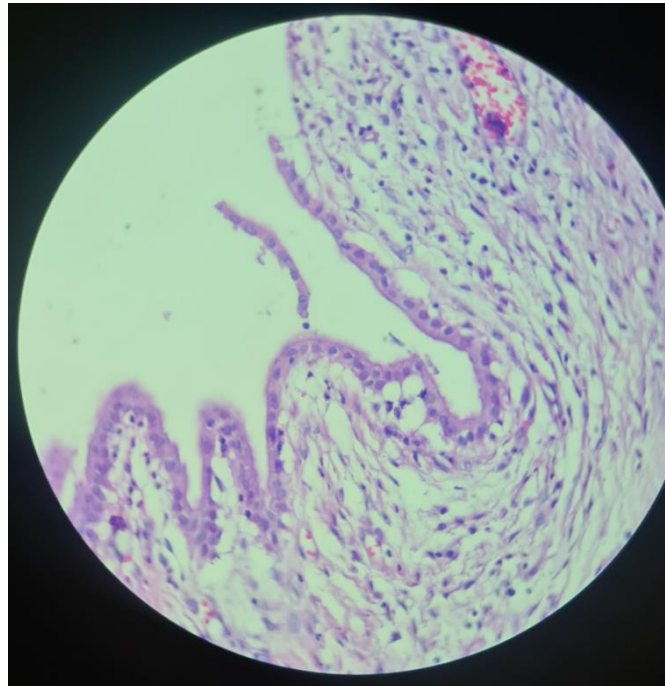


Fig. 6. 40x view of biliary cystadenoma

Post operative care: Patient Symptomatically and clinically improved, as compared to preoperatively. Drain was removed on pod 4. Repeat LFT was done, significant improvement noted in serum bilirubin levels as compared to preoperative levels. Patient was discharged and advised to follow up after 1 month for CBD stent removal.

5. DISCUSSION

Rare liver tumours referred to as biliary cystadenomas show non-specific signs and symptoms [11]. Most frequently demonstrated as asymptomatic and incidental findings result from radiological imaging [12]. In our case, patient was presented as pruritis, pain in abdomen and incidental detection of cystic growth in CBD on radiological imaging.

Pain from intra cystic bleeding or cyst rupture, alongside fever from cyst infection, are common acute presenting symptoms. One of the two possible cause of jaundice is an intraluminal tumour mass or extrinsic compression of bile duct. In our case, jaundice was due to intra luminal growth in CBD.

The recommendation was for complete surgical removal of tumour. because of possibility that a biliary cystadenoma could turn into malignancy

as well as the incapacity to distinguish between benign and malignant masses [4].

Multiloculated and multiseptated biliary cystadenomas originate from the epithelial cell lining the bile ducts or gall bladder. The bile ducts of right hepatic lobe usually the source of these tumours [5]. Even yet benign cystadenomas can become biliary cyst adenocarcinomas if they are not completely removed. in this case also, lesion was arising from hepatic ducts and complete excision of tumour was done to prevent recurrence.

Usually, masses on MRI have low intensity on T1 pictures and high intensity on T2 imaging. The fluid component of cystadenoma can have varying blood content and protein contents, which can affect the CT attenuation and T1 and T2 images. NO diagnostic techniques ensures whether the mass is benign or malignant.

6. CONCLUSION

Any multiloculated cystic liver lesions should be evaluated for the possibility of biliary cystadenoma, especially middle-aged female. For any suspected biliary cyst adenoma, complete resection is preferred course of treatment. It can be quite challenging to

distinguish between benign and malignant tumour based on radiological scans. When total resection is not possible, another alternative is enucleation.

CONSENT

As per international standards or university standards, patient(s) written consent has been collected and preserved by the author(s).

ETHICAL APPROVAL

As per international standards or university standards written ethical approval has been collected and preserved by the author(s).

COMPETING INTERESTS

Authors have declared that no competing interests exist.

REFERENCES

1. Wheeler DA, Edmondson HA. Cystadenoma with mesenchymal stroma (CMS) in the liver and bile ducts. A clinicopathologic study of 17 cases, 4 with malignant change. *Cancer*. 1985;56(6):1434–1445.
2. Lewis WD, Jenkins RL, McDermott WV, et al. Surgical treatment of biliary cystadenoma. A report of 15 cases. *Archives of Surgery*. 1988;123(5):563–568. Soochan D, Keough V, Wanless I, Molinari M. Intra and extra-hepatic cystadenoma of the biliary duct. Review of literature and radiological and pathological characteristics of a very rare case. *BMJ Case Reports*. 2012;1–5.
3. Wu CC, Ho WL, Chen JT, et al. Mesohepatectomy for centrally located hepatocellular carcinoma: an appraisal of a rare procedure. *Journal of the American College of Surgeons*. 1999;188(5):508–515.
4. Levy AD, Murakata LA, Abbott RM, Rohrmann Jr. CA. From the archives of the AFIP: Benign tumours and tumorlike lesions of the gallbladder and extrahepatic bile ducts: Radiologic-pathologic correlation. *Radioic*. 2002;22(2):387–413.
5. Horton KM, Bluemke DA, Hruban RH, Soyer P, Fishman EK. CT and MR imaging of benign hepatic and biliary tumours. *Radioic*. 1999;19(2):431–451.
6. Qiu J, Wu H, Bai Y, et al. Mesohepatectomy for centrally located liver tumours. *British Journal of Surgery*. 2013;100(12):1620–1626.
7. Palacios E, Shannon M, Solomon C, Guzman M. Biliary cystadenoma: ultrasound, CT, and MRI. *Gastrointestinal Radiology*. 1990;15(4):313–316.
8. Marcial MA, Hauser SC, Cibas ES, Braver J. Intrahepatic biliary cystadenoma. Clinical, radiological, and pathological findings. *Digestive Diseases and Sciences*. 1986;31(8):884–888.
9. Thomas KT, Welch D, Pinson W. Effective treatment of biliary cystadenoma. *Annals of Surgery*. 2005;241(5):769–775.
10. Del Poggio P, Jamoletti C, Forloni B, et al. Malignant transformation of biliary cystadenoma: a difficult diagnosis. *Digestive and Liver Disease*. 2000;32(8):733–736.
11. Williamson JML, Rees JR, Pope I, Strickland A. Hepatobiliary cystadenomas. *Annals of the Royal College of Surgeons of England*. 2013;7:507–510.
12. Chandrasinghe PC, Liyanage C, Deen KI, Wijesuriya SR. Obstructive jaundice caused by a biliary mucinous cystadenoma in a woman: a case report. *Journal of Medical Case Reports*. 2013;7: Article 278.

© Copyright (2024): Author(s). The licensee is the journal publisher. This is an Open Access article distributed under the terms of the Creative Commons Attribution License (<http://creativecommons.org/licenses/by/4.0>), which permits unrestricted use, distribution, and reproduction in any medium, provided the original work is properly cited.

Peer-review history:
The peer review history for this paper can be accessed here:
<https://www.sdiarticle5.com/review-history/112801>