



Pulpectomy in a Primary Tooth with Gemination: A Case Report

Farheen Tafti^{1*} and Ashwin Jawdekar¹

¹*Bharati Vidyapeeth (Deemed to be University), Dental College and Hospital, Navi Mumbai,
Maharashtra, India.*

Authors' contributions

This work was carried out in collaboration between both authors. Both authors read and approved the final manuscript.

Article Information

DOI: 10.9734/IJMPCR/2021/v14i330134

Editor(s):

(1) Dr. Syed A. A. Rizvi, Hampton University School of Pharmacy, USA.

Reviewers:

(1) Mona Ionas, University Lucian Blaga of Sibiu, Romania.

(2) Hitesh Chander, PDU Medical College, India.

Complete Peer review History: <https://www.sdiarticle4.com/review-history/73281>

Case Report

Received 20 June 2021
Accepted 25 August 2021
Published 28 August 2021

ABSTRACT

Developmental anomalies may affect the number and morphodifferentiation of teeth. Development of two teeth from one tooth bud gives rise to gemination. Geminated teeth with caries may lead to pulpal pathologies for which extraction may be a preferred treatment. We report a case of geminated maxillary carious primary incisor treated with pulpectomy in a five year-old child.

Keywords: Gemination; fusion; deciduous teeth; pulpectomy; developmental anomaly; primary dentition; double teeth.

ABBREVIATIONS

LA : Local Anesthesia
EDTA : Ethylene Diamine Tetraacetic Acid
OPG : Orthopantomogram
CBCT : Cone-Beam Computed Tomography
GIC : Glass Ionomer Cement

*Corresponding author: E-mail: faru1010@yahoo.com;

1. INTRODUCTION

Any alteration in color, contour, size, shape, number and degree of development of teeth are recognized as developmental anomalies of the teeth which could be due to local as well as systemic factors [1]. The World Health Organization (WHO) has classified these under the category of “the diseases of oral cavity, salivary glands and jaws” in WHO-International Classification of Disease -10 (WHO-ICD-10) (K00-K14). The anomalies of tooth size and form has been listed under section WHO-ICD -10 (K00.2), which includes concrescence, fusion, gemination, dens evaginatus, dens in dente, dens invaginatus, enamel pearls, macrodontia, microdontia, peg-shaped teeth, taurodontism and tuberculum paramolare [2].

Tannenbaum and Alling [3] defined gemination as the formation of equivalent of two teeth from the same follicle, with evidence of an attempt for the teeth to be completely separate. The other names for gemination are double teeth, double formations, joined teeth, fused teeth or dental twinning [4].

Prevalence in the Indian population of gemination is reportedly 0.28% [5]. It is more prevalent in the primary dentition than in the permanent dentition. It is commonly seen in the maxillary anterior region. It causes delayed eruption of the permanent successors [5].

Gemination is usually confused with fusion. Gemination can be differentiated from fusion with the help of Mader's two tooth rule i.e. if the fused teeth are counted as one and the number of teeth present in the arch are less than the normal, this is termed as fusion. It is termed as gemination or ‘fusion with a supernumerary tooth’ if these are counted as one and the number of teeth present in the arch are normal. In gemination, the two halves of the joined crown are mirror images and there exists a buccolingual groove that extends up to the incisal edge, while if there is a fusion between a normal and a supernumerary tooth, there would be differences in the two halves of the joined crowns [6].

Various treatment options for primary double teeth are preventive measures, restorative approach after caries excavation, or a surgical procedure (extraction) depending on the extent of caries as well as the parents' preference [7].

The exact cause of gemination is unknown. However, environmental factors such as trauma,

vitamin deficiency and systemic diseases are considered to be a probable cause [8]. According to Grover and Lorton, local metabolic disturbance during morphodifferentiation of the tooth germ may be the cause [9]. Geminated teeth may develop caries due to the food lodgment in the groove which may progress to pulpal pathologies similar to that in the normal teeth. Extraction of pulpally involved geminated teeth may be a preferred treatment modality owing to their abnormal root canal anatomy and possibility of overretention [10]. We report a case of geminated maxillary carious primary incisor treated conservatively with pulpectomy in a five year-old child.

2. CASE REPORT

A five year-old boy reported to the department of Pediatric and Preventive Dentistry with a chief complaint of decayed teeth. The patient's medical history was non-contributory. There was no family history of dental abnormalities or parental consanguinity. No history of trauma was reported by the parent. General and extraoral examinations contributed no significant findings. Patient's behaviour was rated as positive on Frankl's behaviour rating scale. The past dental history included extraction of a lower molar tooth a few weeks ago; however, the patient was not informed about any developmental anomaly.

On intra-oral clinical examination, complete primary dentition with generalized spacing was observed [Fig. 1]. It was observed that 62 had a developmental anomaly i.e. it had two clinically visible crown structures fused with an evident developmental line; however the total number of teeth present in the dentition was normal, indicative of gemination of 62 [Fig. 2]. Deep occlusal caries were observed on the left mandibular 1st primary molars (74), occlusal caries on the mandibular right 2nd primary molar (85), pit caries on the maxillary 2nd primary molars and mandibular left 1st primary molar (55,65,75), proximal caries on the left maxillary 1st primary molar (64), maxillary primary central incisors (51,61) and missing (lost due to extraction) right mandibular 1st primary molar (84) [Figs. 3, 4]. The patient was advised as Intra oral peri-apical radiograph for 74 and 62 for further diagnosis.

On radiographic examination, 62 showed one root with two pulp canal spaces fusing into one canal space in the apical one-third region of the root structure thus further confirming the dental

anomaly germination [Fig. 5]. The left maxillary permanent lateral incisor (22) also appeared to have a similar anomaly with an evident demarcation line on the crown of the tooth [Fig. 6].

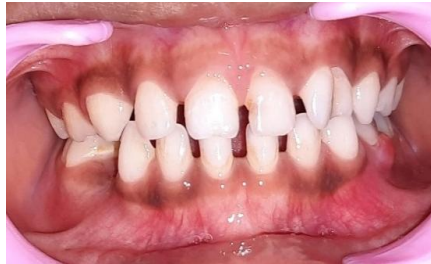

Fig. 1. Pre-operative view of teeth in occlusion

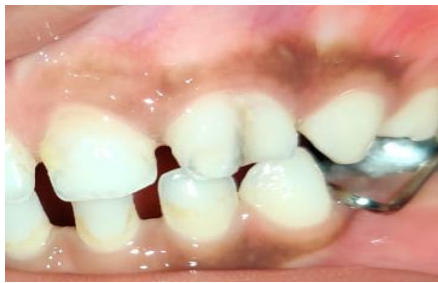

Fig. 2. Pre-operative view of 62

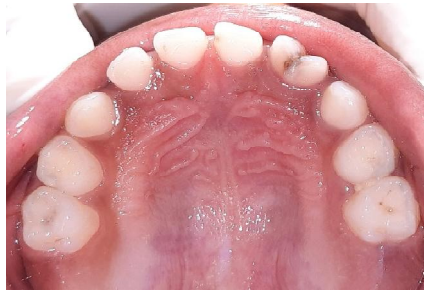

Fig. 3. Pre-operative view of maxillary arch

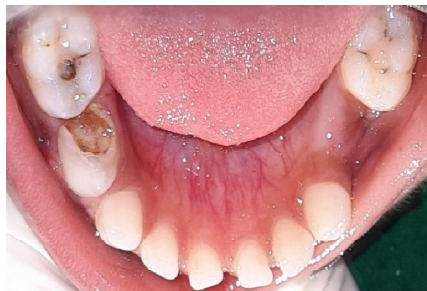

Fig. 4. Pre-operative view of mandibular arch

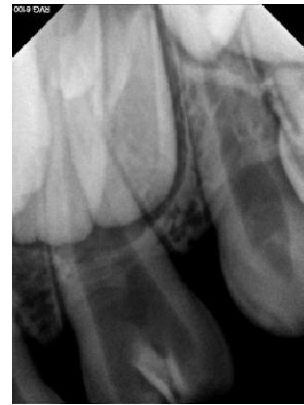

Fig. 5. Pre-operative IOPA of 62

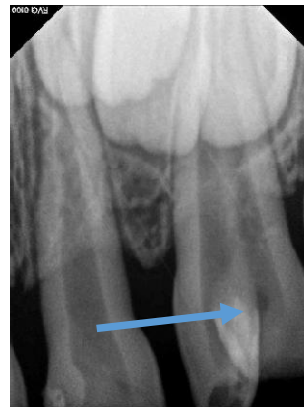

Fig. 6. Pre-operative IOPA of 62 and 22 (Arrow indicates radiolucency of caries suggestive of pulpal involvement)

According to Vertucci's classification (1974) the roots are Type VI and according to Weine's classification (1976) the roots are Type II [11]. Irregular ill-defined radiolucency was seen involving the enamel, dentine and pulp. Periapical region showed no abnormality.

Intra oral peri-apical radiograph of 74 taken a few weeks ago showed root resorption as well as loss of bone in the furcal area [Fig. 7]. The tooth was subsequently extracted.

2.1 Treatment Plan

The summary of treatment plan including the preventive care and schedule of procedures is presented in Table 1. The entire treatment plan, and the possible outcomes i.e. favourable and unfavourable were explained to the patient. A necessary informed consent was taken from the parent and a full mouth rehabilitation started.

Table 1. Treatment summary

Treatment Required	Preventive care	Schedule
GIC restorations: 51,61,54,64, 75,85	Home measures: Tooth-brushing instructions including use of a junior fluoridated toothpaste (600ppm of Fluoride), Tooth mousse (GC Tooth Mousse, Australia) application at bedtime.	Day 1: Consultation, IOPA radiographs, complete oral prophylaxis
Pulpectomy: 62	Dietary counselling: Pertaining to avoiding bottle-feeding at bedtime, reducing sugar exposure between meals, substituting cariogenic food with non-cariogenic food alternatives.	Day 2: 51,61,54,64,75,85 – GIC restorations (GC Gold Label 9, Japan)
Stainless steel crown: 75,85	Office measures: Fluoride varnish 5% NaF (GC MI Varnish, Japan) application with a suggested biannual frequency.	Day 3: 75 – Tooth preparation, mandibular impression for crown and loop space maintainer
Extraction: 74		Day 4: 75 – Cementation of Crown and loop space maintainer 84 – Extraction under LA
Space maintainer: 74, 84 regions		Day 5: 85 – Tooth preparation, mandibular impression for crown and loop space maintainer Day 6: 85 – Cementation of Crown and loop space maintainer Day 7: 62 – Pulpectomy under LA; obturated with Metapex and restored with composite.

2.2 Treatment of 62

After local anesthesia was administered and rubber dam was applied [Fig. 8], caries were excavated in 62 until pulp exposure. The pulp bleeding confirmed irreversible pulpal condition as low red cherry bleeding was seen [12]. Therefore, pulpectomy had to be started; access opening was done with the help of an BR-31SC ISO 001/020 (1.8/19.2) large round bur and SF 31SC ISO 109/015 (4.8/19.2) small straight fissure bur.

Coronal pulp was extirpated with a large spoon excavator and the remaining pulp tissue was removed with the help of a barbed broach size 2 XX Fine Colour: Yellow (MANI, Japan) [13]. Working length was determined with the help of K-files #10 [Fig. 9].

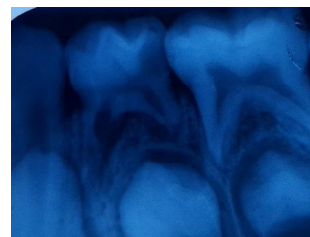


Fig. 7. Pre-operative view of 74

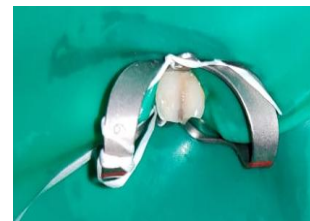

Fig. 8. Rubber dam placement

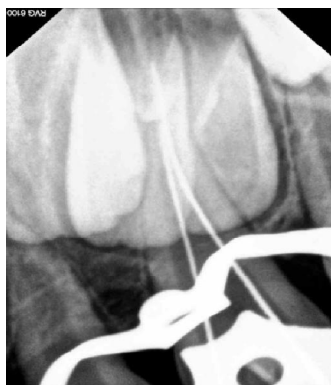

Fig. 9. Working length determination

Mechanical preparation of the canal was initiated with K-file number 15 and was carried out till size number 30 so as to ensure complete removal of the pulp and debris (until clean dentinal shavings) and facilitate complete obturation of the canal. A combination of a chelating agent i.e. EDTA (RC Help, India) and irrigants (1% Sodium hypochlorite, Normal saline) were used for the chemical preparation.

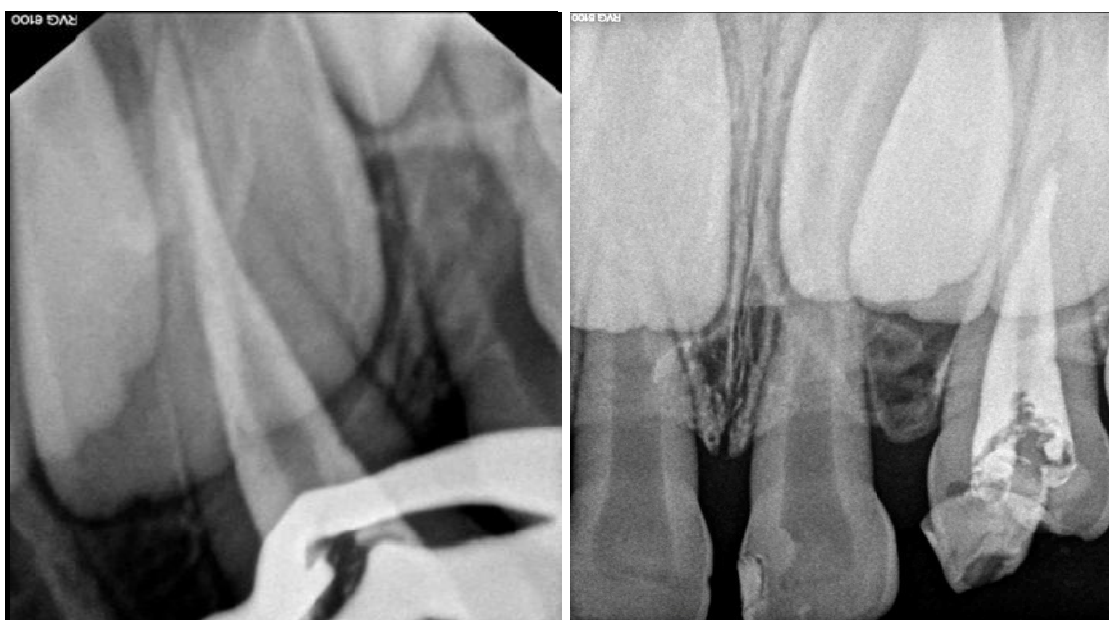Canals were dried with the help of absorbent paper points. After ensuring dryness, the canals were obturated with Metapex Plus (Meta Biomed, Korea). The obturation was assessed with an

intraoral radiograph [Fig. 10a, 10b]. Post-obturation restoration was done with the help of Composite Resin cement (3M ESPE Filtek, USA, Body A2 shade) [Figs. 11, 12] as it could be polished well and has the highest aesthetic appearance when compared to other restorative materials, and as reported by Chisini (2018), also has the lowest annual failure rate i.e. 1.7-12.9% [14].

The post-operative intraoral images are shown in Figs. 13 and 14.

At the 6-month follow-up visit, the child was asymptomatic. An OPG was taken to confirm, if any, related or unrelated consequence. Obturation was visible in the canal of 62. Also, it was observed that mesio-distal width of the left maxillary permanent lateral incisor (22) was evidently larger than normal with a line of demarcation visible indicative of the possibility of two crowns fused together in the place of 22. The root formation of 22 did not appear to have adequately begun [Fig. 15].

The child is advised further follow-up at 3 month intervals. The parents as well as the child appeared satisfied with the outcome of the treatment provided this far.



**Fig. 10a. IOPA radiograph showing obturation of 62 with Metapex
10b. IOPA radiograph showing 22 showing gemination?**

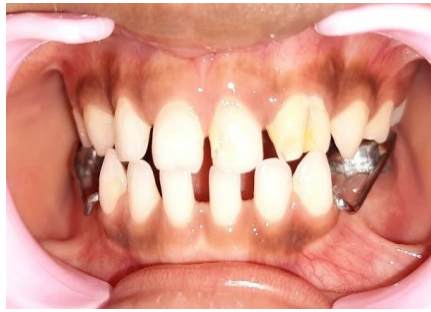

Fig. 11. Post-operative occlusion view

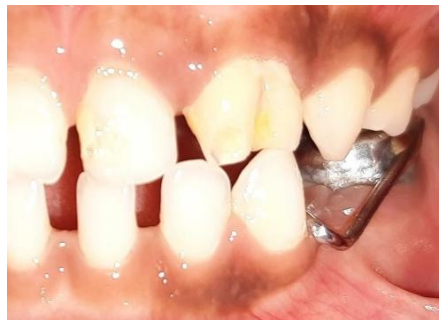

Fig. 12. Post-operative view of 62

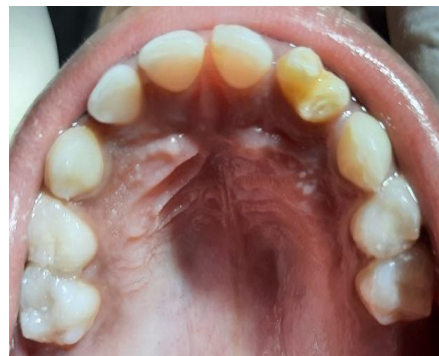

Fig. 13. Post-operative view of maxillary arch

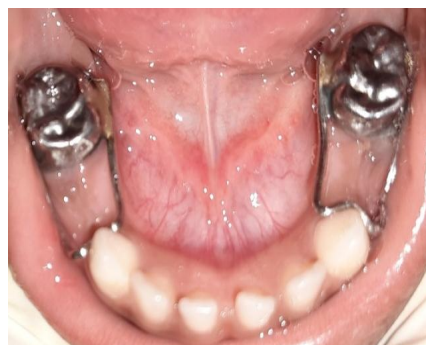

Fig. 14. Post-operative view of mandibular arch

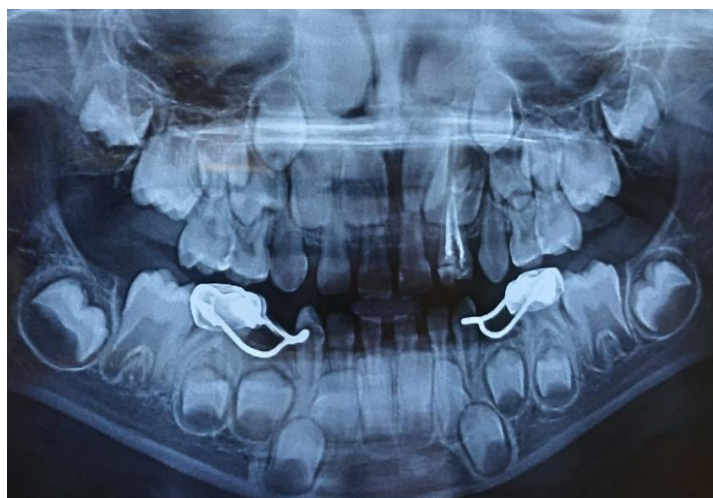


Fig. 15. Follow-up OPG showing successful treatment outcome and suspect gemination of 22

3. DISCUSSION

An anomaly is defined as a disorder of growth or development in the anatomical structures that results in anything different from normal. Development of two teeth from one tooth bud gives rise to germination [15]. Levita's classification is extremely realistic to distinguish between cases of fusion and germination [16].

The tooth anomaly can cause unpleasing aesthetic appearance due to the irregular structure. The developmental groove present on the tooth could lead to food lodgement and thus making the tooth more susceptible to caries and periodontal problems.

The commonly considered treatment options are preventive therapy, caries excavation followed by a appropriate restoration or extraction as per the extent of pathology [9]. However, we could not find any case reports with the treatment option of pulpectomy in a primary tooth with gemination.

In absence of any evidence, the treatment of pulpectomy for the said tooth was guided by the clinician's judgment and patient preference for conservation of the tooth; according to the principles of evidence-based practice [17]. Conservation of a tooth, particularly, an incisor is important from an aesthetic and psychological standpoint [18].

Patient was informed about all the favourable and unfavourable outcomes of the treatment i.e. the tooth could exfoliate on its own during the eruption of its permanent successor. However, if

the counterpart (52) exfoliates and 62 does not show any signs of exfoliation including mobility, the same will be indicated for extraction.

Similar to our finding of 62 and 22 being with anomalies, studies have reported correlation between double teeth in the primary dentition and a numerical variation of the teeth [19,20]. A study conducted by Santanu Mukhopadhyay and Sanjib Mitra reported 27.3% of cases with anomalies in primary dentition showed numerical variations in the permanent dentition [21].

However, further confirmation of the anomaly status of 22 will be possible only after sufficient tooth (root) development. Moreover, OPG being a two-dimensional radiograph, has limitations and a CBCT radiograph may be essential [22].

Follow-up at three months is planned in the Department of Pediatric and Preventive Dentistry to check the status of resorption of the root, assessment of the necessity of extraction and also for routine preventive care. A similar approach is suggested by Yuen et al. [23].

Amongst the other treatments carried out for the child, GIC was used as a restorative material of choice for 75, 85 for various reasons such as chemical adhesion, fluoride release, biocompatibility as well as ease of use and availability [14]. 75,85 being posterior teeth, the chances of saliva contamination could have led to adhesive failure of composite restoration which are known to be technique-sensitive [14]. Therefore, preformed metal crowns were chosen to be placed over them. Moreover, crown and

loop space maintainers were preferred for 75 and 85 as the failure rate of crown and loop space maintainer is reportedly much lower when compared to band and loop space maintainers; a study conducted by Qudeimat et al. [24] reported 22% failure of crown and loops compared to 83% failures of band and loops. Various other studies have shown the failure rate of band and loop ranging from 10-63% [25,26].

4. CONCLUSION

Based on the initial success of our case with a follow-up we can conclude that the conservation of a pulpally involved primary geminated tooth is possible and meets with patient acceptance. Meticulous follow-up including subsequent care (such as its extraction in absence of exfoliation) until the eruption of its successor is essential.

DISCLAIMER

The products used for this research are commonly and predominantly used products in our department as well as our country. There is no conflict of interest between the authors and the manufacturers and trademarks used in the article. This case treatment or the manuscript has not received any funding for publication or otherwise.

CONSENT

As per international standard, parental written consent has been collected and preserved by the author(s).

ETHICAL APPROVAL

As per international standard or university standard written ethical approval has been collected and preserved by the author(s).

COMPETING INTERESTS

Authors have declared that no competing interests exist.

REFERENCES

1. Shrestha A, Marla V, Shrestha S, Maharjan IK. Developmental anomalies affecting the morphology of teeth-a review. *RSBO Revista Sul-Brasileira de Odontologia*. 2015;12(1):68-78.

2. International Statistical Classification of Diseases and Related Health Problems. 10th Revision (ICD-11). Version for 2011.
3. Tannenbaum KA, Alling EE. Anomalous tooth development: case report of gemination and twinning. *Oral Surg Oral Med Oral Pathol*. 1963;16:883-8.
4. Berkovitz BKB, Thomson P. Observation on the aetiology of supernumerary upper incisors in albino ferret. (*Mustelaputorius*). *Arch Oral Biol*. 1971;28:457-63.
5. Neena IE, Sharma R, Poornima P, Roopa KB. Gemination in primary central incisor. *Journal of Oral Research and Reveiw*. 2015;7(2):55.
6. Mader CL. Fusion of teeth. *J Am Dent Assoc*. 1979;98(1):62-4.
7. Bernardi S, Bianchi S, Bernardi G, Tchorz JP, Attin T, Hellwig E, Karygianni L. Clinical management of fusion in primary mandibular incisors: a systematic literature review. *Acta Odontologica Scandinavica*. 2020;78(6):417-24.
8. Nandini DB, Deepak BS, Selvamani M, Puneeth HK. Diagnostic dilemma of a double tooth: a rare case report and review. *Journal of clinical and diagnostic research: JCDR*. 2014;8(1):271.
9. Gover PS, Lorton L. Gemination and twinning in permanent dentition. *Oral Surg Oral Med Oral Pathol*. 1985;59:313-8.
10. Ben Salem M, Chouchene F, Masmoudi F, Baaziz A, Maatouk F, Ghedira H. Fusion or Gemination? Diagnosis and management in primary teeth: a report of two cases. *Case Reports in Dentistry*; 2021.
11. Bansal R, Hegde S, Astekar MS. Classification of root canal configurations: a review and a new proposal of nomenclature system for root canal configuration. *Journal of Clinical & Diagnostic Research*. 2018;12(5).
12. Lejri W, Douki N, Kallel I. Evaluation of a new means of pulpal diagnosis through a prospective study of 133 cases. *Endodontology*. 2019;31(1):21.
13. Moskovitz M, Tickotsky N. Pulpectomy and root canal treatment (RCT) in primary teeth: Techniques and materials. *InPediatric Endodontics*. 2016;71-101.
14. Chisini LA, Collares K, Cademartori MG, de Oliveira LJ, Conde MC, Demarco FF, Correa MB. Restorations in primary teeth: a systematic review on survival and reasons for failures. *International Journal of Paediatric Dentistry*. 2018;28(2):123-39.

15. Terezhalmay GT, Riley Ck. Gemination/ fusion. Quintessence Int. 1999;30:437.
16. Vishal A, Sharma, Neeta. Management of geminated teeth: Case Reports. University Journal of Dental Science. 2017;2:96-98.
17. Dhar V. Evidence-based dentistry: An overview. Contemporary Clinical Dentistry. 2016;7(3):293.
18. Karimi M. Importance of preserving deciduous teeth in childhood. Scientific Archives Of Dental Sciences.2020;3(12).
19. Nik-Hussein, Majid ZA. Dental anomalies in the primary dentition; distribution and correlation with the permanent dentition. J Clin Pediatr Dent. 1996;21:15-9.
20. Whittington BR, Durwad CS. Survey of anomalies in primary teeth and their correlation with the permanent dentition. NZ Dent J. 1996;92:4-8.
21. Mukhopadhyay S, Mitra S. anomalies in primary dentition: Their distribution and correlation with permanent dentition. Journal of Natural Science, Biology and Medicine. 2014;5(1):139.
22. Katheria BC, Kau CH, Tate R, Chen JW, English J, Bouquot J. Effectiveness of impacted and supernumerary tooth diagnosis from traditional radiography versus cone beam computed tomography. Pediatric Dentistry. 2010;32(4):304-9.
23. Yuen SW, Chan JC, Wei SH. Double primary teeth and their relationship with the permanent successors: a radiographic study of 376 cases. Pediatric Dentistry. 1987;9(1):42-8.
24. Qudeimat MA, Sasa IS. Clinical success and longevity of band and loop compared to crown and loop space maintainers. European Archives of Paediatric Dentistry. 2015;16(5):391–396.
25. Tunc ES, Bayrak S, Tuloglu N, Egilmez T, Isci D. Evaluation of survival of three different fixed space maintainers. Pediatr Dent. 2012;34:e97–102.
26. Sasa IS, Hasan AA, Qudeimat MA. Longevity of band and loop space maintainers using glass ionomer cement: a prospective study. Eur Arch Paediatr Dent. 2009;10:6–10.

© 2021 Tafti and Jawdekar; This is an Open Access article distributed under the terms of the Creative Commons Attribution License (<http://creativecommons.org/licenses/by/4.0>), which permits unrestricted use, distribution, and reproduction in any medium, provided the original work is properly cited.

Peer-review history:

*The peer review history for this paper can be accessed here:
<https://www.sdiarticle4.com/review-history/73281>*