

THE EFFECT OF HONEY AND ALOE VERA EXTRACT ON ASPIRIN INDUCED LIVER DAMAGE IN RATS

Adewoga TOS, Sebiomo A

Department of Biological Sciences, Tai Solarin University of Education, Ijagun, Ijebu-Ode, Nigeria

Corresponding author: Sebiomo A
Email: rev20032002@yahoo.com

ABSTRACT

Aim: The aim of this study was to investigate the effect of honey and Aloe vera extract on Aspirin-induced liver damage in albino rats.

Methods: A total of twenty four adult male albino rats weighing between 100 and 150g were divided into six groups. (A, B, C, D, E and F) of four rats each in a group, Rats in Group A served as control and were given water and feeds only. Rats in Group B were given 100mg/kg of aspirin only, 100mg/kg of aspirin was administered to rats in Group C and 1.0ml of Aloe vera was administered to rats in Group D, rats in Group E were administered Aloe vera extract only while rats in Group F were administered with 100mg/kg of aspirin, 1.0ml of Aloe vera and 1.0ml of honey. The administration was done orally.

Results: The results showed significant decrease ($P < 0.05$) in the PCV and haemoglobin level of test groups compared with the control. Groups treated with aspirin had the highest WBC count of $5.83 \times 10^3 (\pm 0.03)$ while the control group had the lowest WBC count of $2.7 \times 10^3 (\pm 0.03)$. Histopathological findings indicate severe dilation of blood vessel, necrosis of vascular connective tissues, wide spread vacuolar degeneration, edema and bile duct hyperplasia. The study revealed that honey and *Aloe vera* extract had hepato protective and hepato curative effects.

Keywords: Honey, Aloe vera, Aspirin, Hepatotoxic, Liver

INTRODUCTION

The liver being the largest internal glandular organ in the body is always in close contact with many harmful substances thus generating interest in natural remedies that are particularly effective in either protecting the liver or curing it from many ailments caused by toxins. Aspirin belongs to the class of drugs called non steroidal anti-inflammatory drugs (NSAIDs) which are mostly used for the management of pain, fever and

inflammation. They are believed to work through the inhibition of at least two variations of cyclooxygenase (COX-1 and COX-2) thus inhibiting the synthesis of prostaglandins (Mahalakshmi et al., 2010). *Aloe vera* is one of the most popular plants used in alternative medicine and is chemically composed of anthraquinone, polysaccharide and carbohydrate (Vinson et al., 2005). It is used for the treatment of ulcers,

hepatitis, neoplasms and wounds. It has also been reported that the plant has anti-inflammatory, antigenotoxic, antioxidative and antiviral properties as well as chemopreventive properties (Kim and Lee, 1997; Zhang and Tizard, 1996; Kim et al., 1999; Lee et al., 2000; Hu et al., 2003). Aloe vera is used for liver problems and is a hepatic stimulant (Aqasoumi et al., 2008; Rajasekaran and Sathishsekar, 2007). Honey a product of honeybees is used as a medicine in many cultures and is known to exhibit a broad spectrum of activities including anti-viral, antibacterial, antioxidant activity and immune stimulant properties (Molan, 2002; Mato et al., 2003; Mabrouk et al., 2004; Khadr et al., 2007). This wonderfully rich golden liquid is the miraculous product of honey bees and naturally delicious alternative to white sugar. Although it is available throughout the year, it is an exceptional treat in the summer and fall when it has just been harvested and it is at its freshest according to Khadr et al., (2007). Liver plays a vital role in cleaning and transforming chemicals but some medicinal agents can damage the organ if given therapeutic or high dosage. Non medicinal agents including industrial and environmental chemicals also lead to hepatotoxicity and are called hepatotoxins. Liver metabolises the xenobiotics by the reduction in fat solubility and alters the biological activity after chemical transformation. Some biochemical markers such as bilirubin, alanine transferase and alkaline phosphatase indicate the normal function of hepatocytes or liver damage (McClatchy et al., 2006). The normal functions of liver can be changed by the actions of toxins or infections. Some agents such as carbon tetrachloride and paracetamol elevate the level of alkaline phosphatase and induce liver injuries (Tobassum et al., 2010). Damage to the liver is determined by the level of aspartate amino transferase and alanine transaminase in the body (Nyblom et al., 2004). Traditional herbal drugs have a great demand in under developed countries due to their efficacy, low cost, availability and lesser adverse effect and they are considered to be "natural" according to Strader et al., (2006). For biological and pharmacological assessment at least twenty percent of plants are used. Due to lack of hepatoprotective drugs in allopathetic medicinal practice, herbal drugs play important roles in the treatment of liver diseases but clinical

trials are required to assess the role of medicinal herbs (Nyblom et al., 2006). Aspirin is widely abused by students, labourers and artisans in Nigeria because of the analgesic effects. This study was therefore designed to determine the effects of *Aloe vera* extract and honey against aspirin induced liver toxicity in rats.

MATERIALS AND METHODS

Collection

Total of 500g of Aloe vera were obtained from a private garden in Ijebu-Ode. While pure honey used was obtained from a commercial store in Ijebu-Ode, Nigeria.

Preparation of Extract

The plant was squeezed to obtain a jelly sap. It was then blended with Vitamin C for preservation and stored in a refrigerator at 4°C.

Preparation of Aspirin Solution

Capsules containing 400mg of aspirin were obtained commercially from a pharmaceutical store located in Ejirin road in Imepe, Ijebu-Ode. 1600mg of this was dissolved in 16ml of distilled water to form the stock solution.

Experimental Design

A total of twenty four adult male albino rats weighing between 100 and-150g were used in this study. The rats were divided into six groups (A, B, C, D, E and F) of four rats each in a group. Rats in Group A serves as control and were given water only, rats in Group B were given 100mg/kg of aspirin only, 100mg/kg of aspirin were administered to rats in Group C and 1.0ml of honey, rats in Group D were administered 100mg/kg of aspirin and 1.0ml of Aloe vera, rats in Group E were administered Aloe vera, extract only while rats in Group F were administered with 100mg/kg of aspirin, 1.0 of Aloe vera and 1.0 ml of honey. The administration was by orally.

Haematological Analysis: At the end of the experiment, the rats were sacrificed and their blood samples collected through cardiac puncture into EDTA bottle for haematological investigation.

Histology: The liver was harvested in 10% formalin fluid for further histopathological examination.

Tissue Processing: The liver tissues obtained were fixed in 10% formal saline for 8 hours, dehydrated, cleared, infiltrated and embedded in paraffin wax. From each specimen, 5 μ m serial sections were cut, with two sections separated by 20 μ m on each glass slide. All sections were stained with heamatoxylin and eosin (Garba et al., 2012).

Statistical Analysis: The data obtained were subjected to 2-way analysis of variance (ANOVA), using statistical package for social sciences version 16.0 (SPSS). The results were expressed as mean \pm standard error of mean (SEM) and p value less than 0.05 was considered significant.

The results showed significant decrease ($P < 0.05$) in the PCV and haemoglobin level of test groups compared with the control (Table, 1). Meanwhile test groups treated with aspirin and honey, aspirin and *Aloe vera* and *Aloe vera* only had increased PCV and haemoglobin levels when compared with the test groups treated with aspirin only. The control groups had the highest PCV and haemoglobin levels of 47.67 ± 1.45 and $16.10 (\pm 0.35)$ (g/dL) respectively. There was also significant reduction ($P < 0.05$) in the RBC counts of the test groups compared with the control which had the highest RBC count of $8.03 \times 10^6 (\pm 0.03)$. Groups treated with Asp +AV+ Honey had the lowest RBC count of $6.43 \times 10^6 (\pm 0.61)$. There was significant increase ($P < 0.05$) in the WBC count of the test groups compared with those of the control compared with the control. Groups treated with aspirin had the highest WBC count of $5.83 \times 10^3 (\pm 0.03)$ while the control group had the lowest WBC count of $2.7 \times 10^3 (\pm 0.03)$ (Table, 1).

RESULTS

Table 1: Effect of Aspirin, Aspirin & Honey, Aspirin+*Aloe vera*, *Aloe vera* only and Aspirin+*Aloe vera*+Honey on PCV, HB, RBC and WBC

GROUP	PCV	HB(g/dL)	RBC($\times 10^6/L$)	WBC($\times 10^6/L$)
Control	47.67 ± 1.45^b	16.10 ± 0.35^b	$8.03 \times 10^6 \pm 0.03^b$	$2.7 \times 10^3 \pm 0.03^a$
Aspirin	40.67 ± 1.45^a	13.57 ± 0.55^a	$6.90 \times 10^6 \pm 0.17^{ab}$	$5.83 \times 10^3 \pm 0.03^b$
Aspirin & Honey	42.67 ± 1.45^{ab}	14.20 ± 0.58^{ab}	$6.90 \times 10^6 \pm 0.23^{ab}$	$3.13 \times 10^3 \pm 0.27^a$
Asp+AV	43.67 ± 1.45^{ab}	14.40 ± 0.58^{ab}	$6.90 \times 10^6 \pm 0.29^{ab}$	$6.15 \times 10^3 \pm 0.72^b$
AV only	42.67 ± 1.45^{ab}	14.60 ± 0.58^{ab}	$6.90 \times 10^6 \pm 0.23^{ab}$	$3.17 \times 10^3 \pm 0.32^a$
Asp+AV+Honey	40.00 ± 2.89^a	13.17 ± 1.01^a	$6.43 \times 10^6 \pm 0.61^a$	$6.40 \times 10^3 \pm 1.04^b$

Each value is the mean of three replicates. Values in the same column followed by the same letters are not significantly different.

NOTE: PCV: Packed cell volume, HB: Haemoglobin count, RBC: Red Blood cells and WBC: White Blood Cell.

In Table 2 there was no significant difference in the level of lymphocytes and neutrophils across all the groups. The control group had significantly higher ($P < 0.05$) monocyte counts [$3.00 \pm 0.58 (\times 10^6/L)$] compared with the test groups. Groups treated with *Aloe vera* only had the lowest monocyte count of $1.00 \pm 0.33 (\times 10^6/L)$. The highest platelet count of $13.67 \times 10^4 (\pm 2.6)$ was obtained in the aspirin treated group while the lowest platelet count of $4.53 \times 10^4 (\pm 0.15)$ was found in the control group. Groups treated with aspirin and honey had the lowest eosinophil count of $1.00 \pm 0.00 (\times 10^6/L)$ compared with all other groups, while groups treated with aspirin only had the highest eosinophil count of $3.00 \pm 0.00 (\times 10^6/L)$ compared with all other groups (Table, 2).

Table 2: Effect of Aspirin, Aspirin & Honey, Aspirin+*Aloe vera*, *Aloe vera* only and Aspirin+*Aloe vera*+Honey on PLAT, LYMP, NEUT, MONO & EOS

GROUP	PLAT($\times 10^6/L$)	LYMP ($\times 10^6/L$)	NEUT($\times 10^6/L$)	MONO($\times 10^6/L$)	EOS($\times 10^6/L$)
Control	$4.53 \times 10^4 \pm 0.15^a$	64.00 ± 0.58^a	30.67 ± 0.33^a	3.00 ± 0.58^b	2.67 ± 0.33^b
Aspirin	$13.67 \times 10^4 \pm 2.6^b$	69.67 ± 2.60^a	25.67 ± 2.03^a	2.00 ± 0.58^{ab}	3.00 ± 0.00^b
Aspirin&Honey	$5.07 \times 10^4 \pm 0.78^a$	69.67 ± 2.60^a	28.67 ± 2.60^a	1.69 ± 0.00^a	1.00 ± 0.00^a
Asp+AV	$9.9 \times 10^4 \pm 1.39^b$	65.67 ± 2.89^a	27.67 ± 4.33^a	2.00 ± 0.00^{ab}	2.67 ± 0.33^b
AV only	$5.4 \times 10^4 \pm 0.75^a$	68.00 ± 5.77^a	28.67 ± 6.06^a	1.00 ± 0.33^{ab}	2.00 ± 0.58^{ab}
Asp+AV+Honey	$10.1 \times 10^4 \pm 1.67^b$	70.00 ± 1.15^a	26.00 ± 2.31^a	2.00 ± 0.58^{ab}	2.00 ± 0.58^{ab}

Each value is the mean of three replicates. Values in the same column followed by the same letters are not significantly different.

Note: PLAT: Platelets, LYMP: lymphocytes, NEUT: Neutrophils, MONO: Monocytes, EOS: Eosinophil counts.

Figs. 1-4 shows the histopathological effects associated with the administration of aspirin, *Aloe vera* extract and honey. Fig. 1-4 show peritortial inflammation, necrosis, congestion of blood vessels, engorgement of sinusoid, periportal and perivascular inflammations, diffused dilation of the sinusoid, vacuolation of hepatocytes and hyperchromatic hepatocytes as obtained in the liver after histopathological examination.

DISCUSSION

This study was designed to determine the effect of *Aleo -vera* extract and honey against aspirin induced liver damage in albino rats. PCV provides the means of estimating the level of anaemia in animals. The decrease in PCV observed across all the experimental groups. It may be as a result of bleeding episodes that arose from drug overdose or sensitivity to drugs. Significant increase in the white blood cell count observed in the Aspirin-*Aleo- vera* group and Aspirin, *Aloe vera* and Honey treated group, when compared with other experimental groups indicate that *Aloe vera* and honey have to an extent, affected the defense mechanism of treated rat, This agrees with the work of Oluyemi et al., (2007) who reported that honey and *Aloe vera* may enhance the immune system in rats. Significant increase in the platelets level observed in the Aspirin only group and Aspirin and *Aloe vera* group is an indication of thrombocytosis; a condition where the faulty stem cells in the bone marrow make excessive platelets, the cause is usually unknown. In the present study, aspirin reduced the circulating red cell counts, haemoglobin and packed cell volume. The histopathological findings revealed that periportal inflammation was observed across all groups, as it has been reported that physical trauma or disease process can cause lyses, resulting in the release of

intracellular enzymes into the blood, periportal and peri vascular inflammation as well as congestion of vessels were observed in the group that was treated with aspirin only when compared with the normal control group and other experimental group is an indication of the hepato toxic effect of aspirin. Congestion and vacuolation of the hepatocytes found in the group treated with aspirin and honey is an indication that honey has little effect on the liver damage in the rats. Rats induced with aspirin and treated with *Aloe vera* showed evidence of active cell division of the hepatocytes, indicating the positive or hepato-curative effect of *Aloe vera* on the liver damaged rats.

CONCLUSION

The study revealed that honey and *Aloe vera* extract had hepato protective and hepato curative effects.

The histopathology of the administration of aspirin, aloe vera extract and honey on the kidney

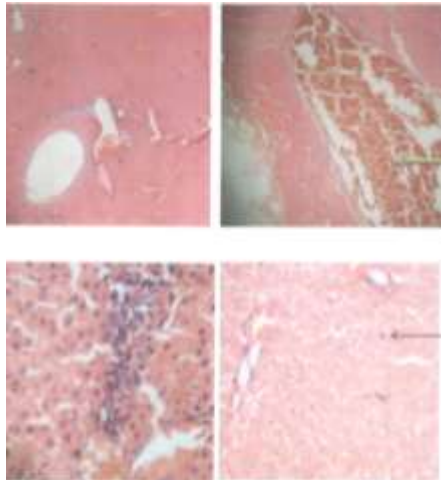


Fig. 1: Liver. Plates show periportal inflammation (blue arrow), focal areas of necrosis (green arrow) and congestion of vessels (black arrow)

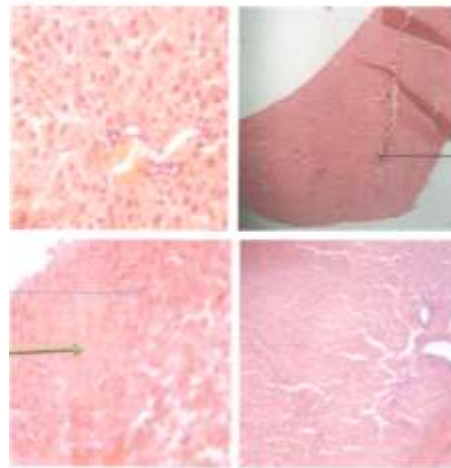


Fig. 2: Plates show multifocal area of necrosis (green arrow) and congestion of vessels (black arrow) as well as engorgement of sinusoid (blue arrow)

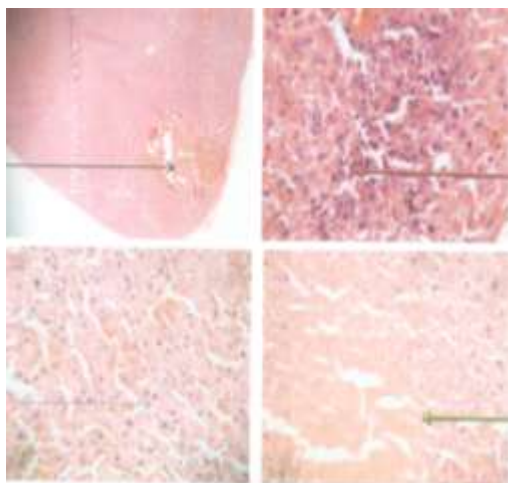


Fig. 3: Plates show periportal as well as perivesicular inflammation (red arrow) diffused dilatation of the sinusoids (blue arrow), multifocal area of necrosis (green arrow) and congestion of vessels (black arrow). Some hepatocytes show evidence of cell division

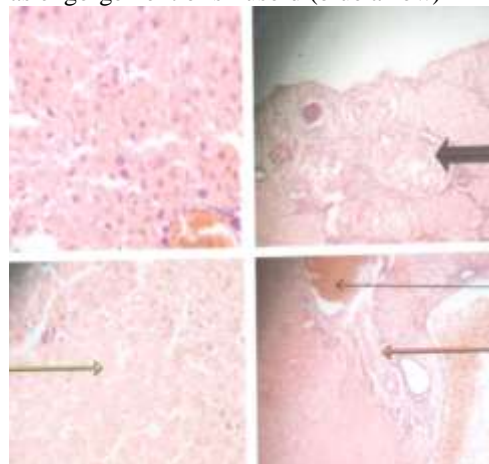


Fig. 4: Plates show periportal inflammation (red arrow), multi focal area of necrosis (green arrow) and congestion of vessels (black arrow). There is a focal area of nodules which contains inflammatory cells along its circumference (black arrow)

REFERENCES

- Garba AM, Mohammed B, Garba SH, Numan AI, Dalori BM (2010). Effect of honey and Aloe vera extract on ibuprofen induced liver damage in Rats. *Journal of Pharmacy and Biological Sciences*. 3: 2278-3008.
- Hu Y, Xu J, Hu Q (2003). Evaluation of antioxidant potential of *Aloe vera* (*Aloe barbadensis* Miller) extracts. *Journal of Agriculture and Food Chemistry*. 51:7788-7791.
- Khadr ME, Karam-Mahdy A, Fatima A, Morsy A, El-Zayat SR, Abd-Allah AA (2007). Antioxidant activity and Hepatoprotective Potential of Black Seed, Honey and Silymarin on Experimental Liver Injuries Induced by CC14 in Rats. *Journal of Applied Sciences*. 7: 3909-3917.
- Kim HS, Lee BM (1997). Inhibition of Benzo[a]pyrene- DNA adduct formation by *Aloe vera* barbadensis Miller. *Carcinogenesis*. 18: 771-776.
- Kim HS, Kacew S, Lee BM (1999). In-vitro chemopreventive effects of plant polysaccharide (*Aloe barbadensis* Miller, *Lentinus edodes*, *Ganoderma lucidum* and *Coriolus versicolor*). *Carcinogenesis*. 20: 1637-1640.
- Lee KY, Weintraub ST, Yu BP (2000). Isolation and identification of a phenolic antioxidant from *Aloe vera* barbadensis. *Free Radical Biology and Medicine*. 28: 261-265.
- Mabrouk GM, Zohny SF, Ali EMM, Ismail EF, Moselhy SS (2004). Bee honey and *Nigella savita* inhibit nitric oxide mediated cytochrome C release and down regulation of connexin 43 induced by methyl nitrosourea in hepatic tissues of Sprague Dawley rats. *Egypt Journal of Biochemistry* 22: 73-87.
- Mahalakshmi R, Rajesh P, Ramesh N, Balasubramanian V, Rajesh-Kannan V (2010). Hepatoprotective activity on *Vitex negundo* Linn. (Verbenaceae) by using Wistar Albino Rats in Ibuprofen Induced model. *International Journal of Pharmacology*. 6: 658-663.
- Mato I, Huidobro JF, Simal-Lozano J, Sancho MT (2003). Significance of non aromatic organic acids in honey. *Journal of Food Protection*. 66: 2371-2376.
- McClatchy A, Kenneth D (2006). *Clinical Laboratory Medicine*, Lippincott Williams and Wilkins. Pp. 288.
- Molan PC (2002). Revival of honey as a medicine. *Honeybee Science*. 23: 153-160.
- Nyblom H, Berggren U, Olsson R (2004). "High AST/ALT Ratio May Indicate Advance Alcoholic Disease Rather Than Heavy Drinking." *Alcohol*. 39: 336-339.
- Nyblom H, Bjornsson E, Simren M, Aldenborg F, Almer S, Olsson R (2006). "The AST/ALT Ratio as an indicator of cirrhosis in patients with PBC", *Liver Int*. 26: 840-845.
- Oluyemi KA, Jimoh OR, Adesanya OA, Omotuyi IO, Josiah SJ, Oyesola TO (2007). Effects of crude ethanolic extract of *Garcinia cambogia* on the reproductive system of male Wistar rats (*Rattus norvegicus*).
- Rajaskeran S, Sathishsekar D (2007). Therapeutic Evaluation of Aloe vera Leaf Gel Extract on Glycoprotein Components in Rats with Streptozotocin Diabetes. *Journal of Pharmacology and Toxicology*. 2: 380-385.
- Strader DB, Seeff LB (2006). Zakim and Boyer Hepatology, T.D. Boyer, T.L. Wright, M.P., Manns Eds. Hepatotoxicity of Herbal Preparations (5th ed). U.S. Saunders-Elsevier, Philadelphia, pp. 551-560.
- Tobassum N, Qazi MA, Shah MY (2010). Curative Potential of Kashni (*Cichorium intybus* Lin) Extract against Carbon Tetrachloride induced Hepatocellular Damage in Rats. *Pharmacology Online*. 2: 971-978.
- Vinson JA, Kharrat HA, Andreoli L (2005). Effects of *Aloe vera* on the human bioavailability of vitamins C and E. *Phytomedicine*. 12: 760-765.
- Zhang L, Tizard IR (1996). Activation of a mouse macrophage cell line by acemannan: The major carbohydrate fraction from *Aloe vera* gel. *Immunopharmacology*. 35: 119-128.